



**QUEEN'S  
UNIVERSITY  
BELFAST**

## Seeing the unseen: could Eulerian video magnification aid clinician detection of subclinical Parkinson's tremor ?

Williams, S., Fang, H., Relton, S. D., Graham, C. D., & Alty, J. E. (2020). Seeing the unseen: could Eulerian video magnification aid clinician detection of subclinical Parkinson's tremor ? *Journal of Clinical Neuroscience*, 81, 101-104. Advance online publication. <https://doi.org/10.1016/j.jocn.2020.09.046>

### Published in:

Journal of Clinical Neuroscience

### Document Version:

Peer reviewed version

### Queen's University Belfast - Research Portal:

[Link to publication record in Queen's University Belfast Research Portal](#)

### Publisher rights

Copyright 2020 Elsevier Ltd.

This manuscript is distributed under a Creative Commons Attribution-NonCommercial-NoDerivs License

(<https://creativecommons.org/licenses/by-nc-nd/4.0/>), which permits distribution and reproduction for non-commercial purposes, provided the author and source are cited.

### General rights

Copyright for the publications made accessible via the Queen's University Belfast Research Portal is retained by the author(s) and / or other copyright owners and it is a condition of accessing these publications that users recognise and abide by the legal requirements associated with these rights.

### Take down policy

The Research Portal is Queen's institutional repository that provides access to Queen's research output. Every effort has been made to ensure that content in the Research Portal does not infringe any person's rights, or applicable UK laws. If you discover content in the Research Portal that you believe breaches copyright or violates any law, please contact [openaccess@qub.ac.uk](mailto:openaccess@qub.ac.uk).

### Open Access

This research has been made openly available by Queen's academics and its Open Research team. We would love to hear how access to this research benefits you. – Share your feedback with us: <http://go.qub.ac.uk/oa-feedback>

Title:

Seeing the unseen: could Eulerian video magnification aid clinician detection of subclinical Parkinson's tremor ?

Authors:

Stefan Williams MBBS, BSc (1)

Hui Fang PhD (2)

Samuel D Relton PhD (1)

Christopher D Graham PhD (3)

Jane E Alty MD, MA, MBBChir (4, 5)

Affiliations

1. University of Leeds, Leeds Institute of Health Science, Leeds, UK
2. Loughborough University, Department of Computer Science, Loughborough, UK
3. Queen's University Belfast, Belfast, Northern Ireland
4. University of Tasmania, Hobart, Australia
5. Leeds Teaching Hospitals NHS Trust UK

Corresponding Author: Stefan Williams

Leeds Institute of Health Science, Worsley Building, University of Leeds, Clarendon Way, Leeds, UK LS2 9LU

Phone: 0113 343 0839 [umswi@leeds.ac.uk](mailto:umswi@leeds.ac.uk) ORCID: 0000-0002-4786-1356

Word count: 1668

Tables: 1 Figures: 1

Running Title: Eulerian video magnification in Parkinson's

Key words: Parkinsonism, Tremor, Clinical Features, Computer Vision, Artificial Intelligence, Eulerian video magnification

Declarations of Interest: none.

This research did not receive any specific grant from funding agencies in the public, commercial, or not-for-profit sectors.

## **Introduction**

Visual assessment contributes to many important clinical judgements in neurology, but fine discrimination can be challenging for the clinician's eye, and visual judgements are vulnerable to inter-rater variability [1]. The developing artificial intelligence technology of computer vision opens up opportunities for computer interpretation of standard video (including smartphone video) to augment the neurologist's visual judgement, without any requirement for special equipment. Eulerian magnification is a computing technique that amplifies very small movements in video, so that motion invisible to the human eye becomes 'revealed' and visible [2]. It can show otherwise unseen movements of respiration, with implications for contactless measurement of respiratory rate [3], but there is only one previous journal report that applies Eulerian magnification to standard video of neurology patients, using it to reveal invisible muscle fasciculation in motor neurone disease [4].

Work with a displacement laser transducer has suggested that apparently atremulous hands of people with Parkinson's can have a subclinical tremor, distinct from physiological tremor, which is not visible by eye [5]. In addition, some patients report a sensation of 'internal tremor' [6]. Our previous report of a single patient and control suggested that Eulerian magnification could reveal an apparent Parkinsonian tremor that was not visible in the original video [7]. As such, it is possible that Eulerian magnification might allow visualisation of subclinical pathological tremor in a contactless manner, without special equipment. We aimed to assess the potential for the technique to enable clinicians to detect very low amplitude, otherwise invisible Parkinson's tremor. We hypothesised that a greater number of apparently atremulous Parkinson's hands would have the appearance of a Parkinsonian tremor after Eulerian video magnification compared with the hands of control participants.

## **Methods**

All participants provided written, informed consent, and the study was approved by the London-Fulham Research Ethics Committee of the United Kingdom Health Research Authority (IRAS project ID number: 224848).

Standard smartphone (iPhone) videos of 48 hands were collected, in which no tremor was seen at the time of recording. 22 hands were from 11 healthy control participants (no neurological diagnoses or other diagnoses that might cause tremor, no medication likely to cause tremor). 26 hands were from 17 participants with idiopathic Parkinson's disease (previously diagnosed by a movement disorder specialist neurologist according to MDS criteria [8]), who were subjectively and objectively in the 'on' state at the time of video recording. The total number of Parkinson's hands was not 34 because 8 participants had obvious visible tremor in one hand, and those hands were excluded from the sample. Each video was 15 seconds duration (60 frames per second, 1920x1080 pixel resolution), and showed the hand resting over a chair arm (dorsum of hand and fingers visible). The smartphone was placed on a tripod, at a distance from the hand that was not tightly defined, but approximately 1m.

The videos were processed by computer using an Eulerian video magnification algorithm (freely available online) [2] to amplify video pixel movements between 3 and 7 Hz, by a factor of 20, as outlined previously [7]. The original videos, and the videos after Eulerian magnification, were rated by three independent UPDRS-certified movement disorder specialist neurologists (clinical raters), in randomised order, with raters blinded to patient / control status. The raters were asked, "does the hand in the video have the appearance of a Parkinsonian tremor? (yes/no)".

We analysed the proportion of hands correctly classified as Parkinsonian or not before and after amplification by McNemar's test for each rater, with the assumption that an appearance of Parkinsonian tremor is a correct classification for patients but not controls. In addition, McNemar's test was formulated as a mixed effects logistic regression model with combined datasets. The model used correct classification as the outcome with fixed effects for pre/post-amplification and rater identity, plus a random effect for video number. The fixed effect for amplification provides an odds ratio for the impact amplification has on correct classification estimated over all collected data.

## **Results**

Participant details are given in **Table 1**.

	<b>Parkinson's</b>	<b>Controls</b>
<b>Number of participants</b>	17	11
<b>Hands (no obvious tremor at time of recording) [left:right]</b>	26 [12:14]	22 [11:11]
<b>Mean age [SD], years</b>	69 [11.3]	51 [22.8]
<b>Male:Female</b>	18:8	8:14
<b>Median years since diagnosis</b>	3.8	N/A
<b>No history of previous tremor in filmed hand</b>	8	22
<b>History of previous intermittent tremor in filmed hand</b>	18	0
<b>'Internal tremor' sensation in filmed hand</b>	4	0
<b>Mean age for hands rated 'Parkinsonian tremor' after Eulerian magnification</b>	66	57

**Table 1. Participant (hand) characteristics**

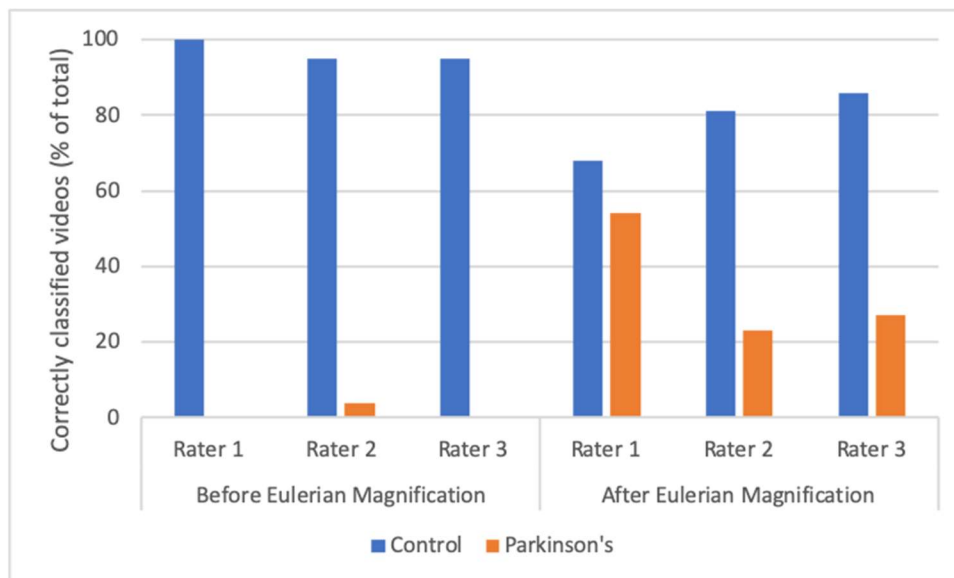
Parkinson's: idiopathic Parkinson's disease. 'No obvious tremor at time of recording' refers to hands in which the investigator (SW) did not see tremor during video recording. SD = standard deviation. 'No history of previous tremor' and 'History of previous intermittent tremor' refer to patient reported symptoms (disease history).

Prior to Eulerian magnification, the original videos were judged to show Parkinsonian tremor in the following number of Parkinson's participant hands: 0/26 (rater 1); 1/26 (rater 2); 0/26 (rater 3), and the following number of control participant hands: 0/22 (rater 1); 1/22 (rater 2); 1/22 (rater 3). The single control hand rated as tremulous by rater 2 was also the single hand rated as tremulous by rater 3.

After Eulerian magnification, the following number of Parkinson's hands were judged to show Parkinsonian tremor: 14/26 (rater 1), 6/26 (rater 2), 7/26 (rater 3), and the following number of control participant hands were judged to show Parkinsonian tremor: 7/22 (rater 1); 4/22 (rater 2); 3/22 (rater 3). **Video 1** shows an example of a Parkinson's participant hand and a control participant hand before and after Eulerian magnification. Each

participant hand appears atremulous in the original video, but only the Parkinson's participant hand appears to have a typical Parkinsonian tremor after movement amplification.

The group mixed effects model combining scores for all three raters showed a significantly higher proportion of correctly classified hands after Eulerian magnification, (OR = 2.67; CI = [1.39, 5.17];  $p < 0.003$ ), **Figure 1**. For each of the three individual raters, the proportion of correctly classified hands increased after Eulerian magnification, although did not reach significance when analysed in isolation ( $p = 0.08, 0.36, 0.09$ ).



**Figure 1. Eulerian video magnification improves clinician classification of hands as Parkinsonian or control**

The overall proportion of correctly classified hand videos is increased after Eulerian magnification,  $p < 0.003$  (McNemar test mixed effects logistic regression model). Correct classification is defined as Parkinsonian tremor in Parkinson's hands and no Parkinsonian tremor in control hands (raters blinded to diagnosis). Note that some control hands were incorrectly classified after amplification (lower blue bars on right side of graph), but *all* Parkinson's hands except one (for one rater) were incorrectly classified prior to amplification (lack of orange bars on left side of figure).

## Discussion

Tremor is defined as an involuntary, rhythmic, oscillatory movement of a body part [9], and it can exist at a subclinical amplitude [5]. When we applied Eulerian video magnification to hands that initially appeared atremulous, the result was the appearance of Parkinsonian tremor in some of the Parkinson's hands but also some of the healthy control hands. However, clinicians saw a greater number of Parkinsonian tremors after magnification in Parkinson's hands compared with control hands. In other words, Eulerian magnification revealed a significant group difference that was not visible in the original videos. After Eulerian video magnification, clinicians were able to correctly classify a greater proportion of hands as Parkinsonian or not ( $p < 0.003$ ).

Tremor can be composed of several elements: the mechanical component (natural frequency), mechanical-reflex component (driven by increased gain of the monosynaptic reflex), and central component(s) (aberrant oscillatory activity transmitted along the motor system from one or more central nervous system structures) [10]. Eulerian magnification would be expected to amplify any of these components that are present at a subclinical level. Physiological tremor consists of mechanical and central components, while Parkinson's tremor is largely central [10]. One interpretation of our findings is that Eulerian magnification reveals more subclinical tremor in Parkinson's, because physiological tremor is present in both controls and Parkinson's, but an additional subclinical central tremor component is present in some Parkinson's patients [5]. As such, Eulerian magnification may represent a first step towards contactless visualisation of subclinical pathological tremor. A recent publication used computer vision algorithms to estimate hand tremor frequency from video [11], but that was a study of visible tremor, distinct from the present study in which hands appear atremulous in the original videos.

A major strength is that the method is entirely contactless, and simply requires standard video recorded with a smartphone. However, there are several limitations. We have reported a significant group difference, but in its current form this method is not a diagnostic test or biomarker (it lacks specificity and sensitivity). The study tested 'classification' of both Parkinson's and control hands. However, it is important to acknowledge that the potential implications of misclassification are not the same for control and Parkinson's hands. Erroneously classifying healthy control hands as Parkinsonian runs the risk of considerable psychological distress, so that any future development of Eulerian magnification would require better separation of signal from 'noise', to reduce false positive appearances. We did not record accelerometer or EMG as a form of 'gold standard' comparator. However, previous work on subclinical tremor utilised displacement laser transducer [5] or spiral drawing [12], and the ability of accelerometer or EMG to detect subclinical tremor is unclear. The patient group had a higher mean age

than the control group, although this was also true among hands rated as tremulous post-magnification, so age differences likely do not explain our results. Our patient group was heterogeneous, e.g. the presence/absence of 'internal tremor' sensation, or visible tremor in the contralateral hand, and it may be that more uniform subgroups could identify a stronger or more specific effect of Eulerian magnification.

Some idiopathic Parkinson's patients never develop clinical tremor, and there is a recognised distinction between the predominant resting tremor subtype and the postural instability gait difficulty subtype of the disease [13]. Thus, the assumption that Parkinsonian tremor after Eulerian magnification is the correct classification for Parkinson's hands may not be an appropriate one for all patients. The algorithm cannot be expected to reveal subclinical movement that was never there and may never be so.

Although visible tremor was not seen in person at the time of recording, one rater saw visible tremor in one Parkinson's hand video prior to amplification and two raters saw visible tremor in one control hand video prior to amplification, so that the pre-amplification hand videos cannot be described as entirely atremulous. However, nearly all were rated as 'no tremor' pre-amplification and the initial rater disagreement serves to highlight the limitations of standard clinician visual assessment.

The current study broadens the knowledge of Eulerian magnification. Apparent revealed tremor is present in Parkinson's and control hands, so that our method would not be of direct clinical use in its current iteration. However, on average, Eulerian magnification improves clinician ability to identify apparently atremulous hands as Parkinsonian. A key question for future research is how to distinguish physiological from pathological tremor after Eulerian magnification. To answer this, future work is required on signal processing after magnification, comparison with weight loading and posture; and computer measurement of post-magnification video (rather than purely clinician visualisation). More broadly, the results support the idea that Eulerian magnification might provide the basis for future methods to visualise other subclinical neurological signs.

## **References**

1. Bajaj NPS, Gontu V, Birchall J, *et al.* Accuracy of clinical diagnosis in tremulous parkinsonian patients: a blinded video study. *Journal of Neurology, Neurosurgery & Psychiatry.* 2010; 81: 1223-1228.



2. Wu H, Rubinstein M, Shih E, *et al.* Eulerian video magnification for revealing subtle changes in the world. *ACM Trans. Graph.* 2012; 31 (4).
3. Antognoli L, Marchionni P, Spinsante S, *et al.* Enhanced video heart rate and respiratory rate evaluation: standard multiparameter monitor vs clinical confrontation in newborn patients. *IEEE International Symposium on Medical Measurements and Applications (MeMeA).* 2019; 1-5.
4. Van Hillegondsberg L, Carr J, Brey N, Henning F. Using Eulerian video magnification to enhance detection of fasciculations in people with amyotrophic lateral sclerosis. *Muscle & nerve.* 2017; 56 (6): 1063-7.
5. Beuter A, Barbo E, Rigal R, Blanchet PJ. Characterization of subclinical tremor in Parkinson's disease. *Mov Disord.* 2005; 20 (8): 945-950.
6. Shulman LM, Singer C, Bean JA, Weiner WJ. Internal tremor in patients with Parkinson's disease. *Mov Disord.* 1996; 11 (1): 3-7.
7. Williams S, Fang H, Alty J, Qahwaji R, Patel P, Graham CD. A smartphone camera reveals an 'invisible' Parkinsonian tremor: a potential pre-motor biomarker? *Journal of Neurology.* 2018; 265 (12): 3017-8.
8. Postuma RB, Berg D, Stern M, *et al.* MDS clinical diagnostic criteria for Parkinson's disease. *Mov Disord.* 2015; 30(12): 1591-1601.
9. Bhatia KP, Bain P, Bajaj N, *et al.* Consensus Statement on the classification of tremors. from the task force on tremor of the International Parkinson and Movement Disorder Society. *Mov Disord.* 2018; 33(1): 75-87.
10. Vial F, Kassavetis P, Merchant S, *et al.* How to do an electrophysiological study of tremor. *Clin Neurophysiol Pract.* 2019; 4: 134-142.
11. Pintea SL, Zheng J, Li X, Bank PJ, van Hilten JJ, van Gemert JC. Hand-tremor frequency estimation in videos. In *Proceedings of the European Conference on Computer Vision (ECCV) 2018*; 213-28.
12. Louis ED, Meyers JH, Badejo OM, *et al.* Comparative burden of subclinical tremor in a cohort of normal individuals stratified by familial risk for essential tremor. *Neuroepidemiology.* 2018; 50(1-2): 41-6.
13. Zaidel A, Arkadir D, Israel Z, Bergman H. Akineto-rigid vs. tremor syndromes in Parkinsonism. *Curr Opin Neurol.* 2009;22(4):387-393.

### **Video Legend**

#### **Video 1. Eulerian magnification reveals apparent Parkinsonian tremor.**

(Legend) The first pair of videos are from a participant with a diagnosis of idiopathic Parkinson's disease. Prior to magnification (left frame), no movement is seen. Following Eulerian magnification of the same video (right frame), movement with an appearance of Parkinsonian tremor is seen. The second pair of videos are from a control. Movement is seen after Eulerian magnification (right frame) but does not have the appearance of a Parkinsonian tremor.

### **Acknowledgement**

We would like to thank Dr Jeremy Cosgrove and Dr Steven Butterworth for providing clinical rating of videos.

### **Authors' Roles**

Stefan Williams: conception and design, execution, writing of the first draft, review and critique

Hui Fang: conception and design, execution, review and critique

Samuel D Relton: statistical analysis, review and critique

Christopher D Graham: design, review and critique

Jane E Alty: conception and design, execution, clinical rating of videos, review and critique