

© Anıl Kuvandık,  
© Ecenur Özcan,  
© Simay Serin,  
© Hülya Sungurtekin

## Creutzfeldt-Jakob Disease After the COVID-19 Vaccination

### COVID-19 Aşısı Sonrası Creutzfeldt-Jakob Hastalığı

Received/Geliş Tarihi : 12.10.2021  
Accepted/Kabul Tarihi : 21.12.2021

Anıl Kuvandık, Ecenur Özcan, Simay Serin,  
Hülya Sungurtekin  
Pamukkale University Faculty of Medicine,  
Department of Anesthesiology and Reanimation,  
Denizli, Turkey

Anıl Kuvandık MD, (✉),  
Pamukkale University Faculty of Medicine,  
Department of Anesthesiology and Reanimation,  
Denizli, Turkey

E-mail : anilkuvandik@gmail.com

Phone : +90 544 636 99 32

ORCID ID : orcid.org/0000-0002-7555-6076

**ABSTRACT** Reports of neurological problems are increasing for the clinical presentation of COVID-19. The clinical presentation reported in this study seemed to be a combination of nonspecific complications of the systemic disease, inflammation of the cerebrovascular system, and the effects of a direct viral infection. Creutzfeldt–Jakob disease, a spongiform encephalopathy caused by prions, is characterized by a severe neurological destruction, which has an extremely high mortality. In this publication, we presented a patient who was admitted to the Pamukkale University Anesthesiology Intensive Care Units with the neurological findings that developed after the COVID-19 vaccine (CoronaVac, Sinovac Life Sciences, Beijing, China). The patient died due to the progressive neurological disorders. In cases where rapidly progressive neurological disorders are observed, Creutzfeldt–Jakob disease should be considered and the role of immunity-related conditions in the progression of the disease should be investigated.

**Keywords:** Covid-19, Vaccine, Creutzfeldt–Jakob disease, Prion protein

**ÖZ** COVID-19 hastalığının klinik seyrinde gelişen nörolojik problemlerle ilgili raporlar artmaktadır. Bu klinik tablo, sistemik hastalığın spesifik olmayan komplikasyonları, serebrovasküler sistem iltihabı veya doğrudan viral enfeksiyonun etkilerinin bir kombinasyonu gibi görünmektedir. Prionların neden olduğu süngerimsi bir ensefalopati olan Creutzfeldt-Jakob hastalığı, şiddetli nörolojik yıkım ile karakterizedir ve son derece yüksek bir ölüm oranına sahiptir.

Bu yayında, Pamukkale Üniversitesi Anesteziyoloji Yoğun Bakım Ünitelerine COVID-19 aşısı (CoronaVac, Sinovac Life Sciences, Beijing, China) sonrası gelişen nörolojik bulgularla başvuran bir hastayı sunduk. Hasta ilerleyici nörolojik bozukluklar nedeniyle öldü.

Hızla ilerleyen nörolojik bozuklukların görüldüğü durumlarda Creutzfeldt-Jakob hastalığı düşünülmeli ve bağışıklıkla ilgili durumların hastalığın ilerlemesindeki rolü araştırılmalıdır.

**Anahtar Kelimeler:** Covid-19, aşı, Creutzfeldt-Jakob hastalığı, Prion proteini

## Introduction

Neurological effects from COVID-19 infections are now documented in scientific studies.(1) Neurological manifestations may be related such as direct effects of the virus on the nervous system, para-post-infectious immune mediated disease, and neurologic complications of the systemic effects of COVID-19.(2)

Unvaccinated individuals are at higher risk of serious illness from COVID-19 infection, which can cause temporary or long-term neurological effects in some patients. Autoimmunity and the opposing condition, metabolic syndrome, are well known adverse events caused by vaccines.(3) COVID-19 infections are related to the induction of autoantibodies and autoimmune disease which makes it more than reasonable a vaccine can do the same. There is no evidence that the

COVID-19 vaccines lead to neurodegenerative diseases as far as we know.

In this case report, a patient who was diagnosed with Creutzfeldt-Jakob disease (CJD) after Covid-19 vaccine was examined.

## Case Report

A 82-year-old female patient with a known diagnosis of hypertension and dementia started to have tremors and weakness on the right side of her body. The patient's findings emerged one day after the first dose of COVID-19 CoronaVac vaccine was administered. She admitted to the hospital with the addition of symptoms such as regression in her state of consciousness, inability to recognize the people

around her, impaired vision, impaired place-time orientation and meaningless shouts at the following month. She was admitted to our neurology unit hospital with a diagnosis of encephalitis and subdural hematoma.

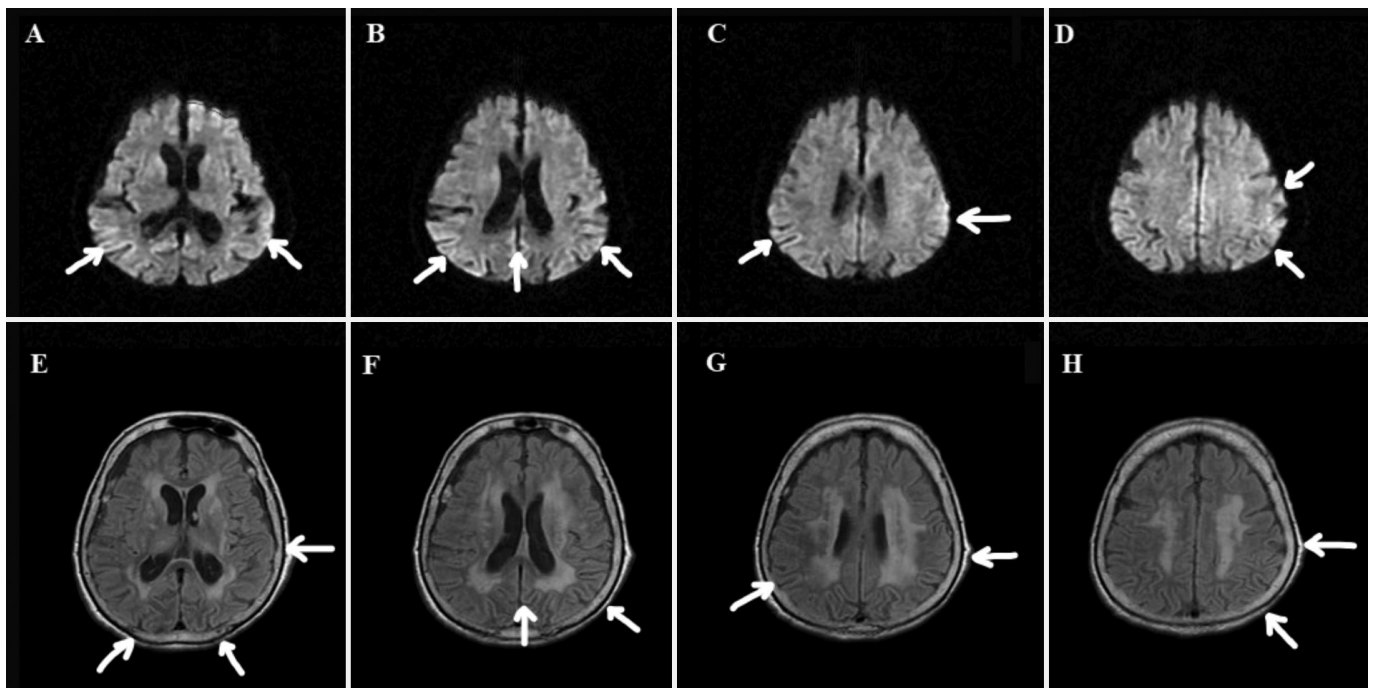
On admission, she has myoclonic contractions and disorientation in her right extremities. She has no findings in cranial nerve examinations. Clonus, rigidity and hyperreflexia were present in the right half of the body. Glasgow Coma Scale (GCS) was 10/15 on neurological examination. Laboratory studies such as liver and kidney function tests, electrolytes, complete blood count, blood gas analysis, coagulation tests, thyroid function tests, autoimmune markers, viral encephalitis markers were done. CSF samples were taken and examined. Electroencephalography (EEG) examination was performed. Blood, urine, respiratory secretions and cerebrospinal fluid (CSF) cultures were made. No abnormal laboratory finding was found in blood tests. Autoimmune encephalopathy panels were negative. EEG showed paroxysmal mixed sharp and sharply slow paroxysms, diffuse slowing of cerebral bioelectrical activity without lateralization and localization. She received pulse steroid and intravenous immunoglobulin (IVIg) therapy with a diagnosis of autoimmune encephalitis in the neurology service. When GCS dropped to 4 in the neurology service, she was intubated and hospitalized in our intensive care unit. Brain and thorax computed tomography

and cranial MRI examinations were performed. She received empirical antibiotics and antiepileptic therapy for meningitis prophylaxis in addition to pulse steroid and intravenous IVIg therapy in the intensive care unit. Transesophageal echocardiography was performed for infective endocarditis. Diffusion-weighted MRI revealed cortical diffusion restriction in the left parietal, occipital, temporal lobes and the right occipital lobe. In the FLAIR examination, hyperintensity was observed in the same regions (Figure 1).

The patient was diagnosed with sporadic CJD after the 14-3-3 protein test was positive, MRI findings, physical examination, and evaluation of the clinical history. As a result of her examinations, viral encephalitis, autoimmune encephalitis and subdural hematoma were excluded. The patient died as a result of the progressive course of the disease.

## Discussion

COVID-19 is an unprecedented threat that is straining health system capacities around the world. Neurological symptoms develop in 17.3% to 36.4% of patients in the acute phase of the disease, and 25% of these are caused by central nervous system involvement. Central nervous system involvement is mostly seen as viral meningitis or



**Figure 1.** Brain MRI findings in this case. A,B,C,D: Diffusion-weighted MRI shows cortical diffusion restriction in the left parietal, occipital, temporal lobes and the right occipital lobe. E,F,G,H: FLAIR examination shows hyperintensity in the same regions

encephalitis. The most common neurological symptoms are headache, dizziness and changes in consciousness.(4)

Possible mechanisms in the neurological involvement of COVID-19; viral encephalitis, systemic inflammation, dysfunction of peripheral organs and cerebrovascular changes. These mechanisms enhance neurological symptoms by aggravating a pre-existing neurological disorder or initiating a new disease.(5) In COVID-19, there is an increase in cytokines and inflammatory mediators resulting from systemic inflammation. Systemic inflammation, on the other hand, supports cognitive decline and neurodegenerative diseases.(6) Authors(7) found prion related sequences in the COVID-19 spike protein which were not found in related coronaviruses. It was also reported a case of prion disease, Creutzfeldt-Jakob disease, initially occurring in a man with COVID-19.(1)

Vaccination is an effective strategy to reduce the burden of preventable diseases. However, many clinical studies have revealed that various vaccines may be associated with different neurological disorders and autoimmune pathologies. Although some studies show that neurological disorders that develop after vaccination may not be related to the vaccine, these results may be coincidental.(8) In addition, reporting of post-vaccine-related adverse events may increase the hesitation of the public about vaccination and support vaccination opposition. No article has been found in the literature about the Covid-19 vaccines causing encephalitis.

Creutzfeldt-Jakob disease is a very rare, rapidly progressing, contagious neurodegenerative disease with a mortality rate of 100% caused by prion proteins. Although CJD is generally sporadic, it can occur in 10% of cases with familial autosomal dominant inheritance.(9) The neuron losses in the gray matter and the many vacuoles in the central nervous system are responsible for the classic sponge-like appearance of the brain and the emergence of specific clinical symptoms in CJD. This infectious disease with fatal consequences is of particular importance as it can be iatrogenically transmitted to healthcare personnel and other patients.(10)

Sporadic CJD usually begins with nonspecific symptoms in older ages. Often there are personality disorders, depression, sleep disorders and weight loss. Behavioral problems and cognitive dysfunction are important symptoms. Brain biopsy is the gold standard in diagnosis. Since surgery is risky and samples cannot be taken from

the affected area all the time, brain biopsy can be performed in uncertain diagnoses after all non-invasive diagnostic methods are performed.(11) Checking 14-3-3 protein and tau protein in CSF is important in the diagnosis of sporadic CJD. These proteins are markers of neuronal destruction and their concentration increases in the later stages of the disease. In the absence of clinical signs, the 14-3-3 protein has no value and is not specific for CJD. Real-time quaking-induced conversion (RT-QuIC) test is an examination that detects the abnormal scrapie form of the prion protein (PrPsc) and provides a definitive diagnosis.(12) It was used The Centers for Disease Control and Prevention's (CDC) criteria for CJD diagnosis in our case.(13) Our patient had neurological symptoms and cognitive dysfunction. CSF examination was positive for 14-3-3 protein. We did not have the opportunity to do the RT-QuIC test.

Periodic sharp wave complexes (PSWC) in EEG are found in 2/3 of patients with sporadic CJD and are among the diagnostic criteria.(13) The spikes on the EEG are independent of typical signs of myoclonic seizures and are associated with the fusion of dendritic membranes in neurons. Although PSWCs are initially lateralized, they are seen in bilateral frontal localization in progressive disease.(14) In our case, mixed and slow sharp waves observed in EEG were not lateralized. In MRI, the high intensity signal pattern in T2 / FLAIR sequences is compatible with astrogliosis and hyperintensity in diffusion-weighted imaging with the formation of vacuoles and prion protein in the brain. MRI images correlate with symptoms and clinical findings, but hyperintensity decreases in the later stages of the disease and cortical atrophy may be the only finding. Therefore, in the absence of specific imaging findings, if CJD is considered in the differential diagnosis, attention should be paid to when the clinical findings begin.(15) In our case, cortical diffusion restriction was detected in the left parietal, occipital, temporal lobes, and right occipital lobe on MRI. Hyperintensity was observed in the same regions in FLAIR examination.

The onset of acute neurological symptoms after Covid-19 vaccination suggested that there might be an adverse effect related to the vaccine. Suppression of immunity after vaccination may have accelerated the emergence of prion disease or the onset of the disease may be coincidental. In order for CJD diagnosis to be associated with the vaccine, the cause-effect relationship between them must be revealed. Therefore, further studies are needed in this area.

**Ethics****Peer-review:** Externally peer-reviewed.**Authorship Contributions**Surgical and Medical Practices: A.K., E.Ö., S.K., H.S.,  
Concept: A.K., Design: A.K., Data Collection and Process:A.K., E.Ö., Analysis or Interpretation: A.K., E.Ö., S.K., H.S.,  
Literature Search: A.K., E.Ö., Writing: A.K., E.Ö.**Conflict of Interest:** No conflict of interest was declared by  
the authors.**Financial Disclosure:** The authors declared that this study  
received no financial support.**References**

1. Young MJ, O'Hare M, Matiello M, Schmahmann JD. Creutzfeldt-Jakob disease in a man with COVID-19: SARS-CoV-2-accelerated neurodegeneration? *Brain Behav Immun.* 2020;89(January):601–3.
2. Ellul MA, Benjamin L, Singh B, Lant S, Michael BD, Easton A, et al. Neurological associations of COVID-19. *Lancet Neurol* [Internet]. 2020;19(9):767–83. Available from: [http://dx.doi.org/10.1016/S1474-4422\(20\)30221-0](http://dx.doi.org/10.1016/S1474-4422(20)30221-0)
3. Classen JB. Review of Vaccine Induced Immune Overload and the Resulting Epidemics of Type 1 Diabetes and Metabolic Syndrome, Emphasis on Explaining the Recent Accelerations in the Risk of Prediabetes and other Immune Mediated Diseases. *J Mol Genet Med.* 2014;02(s1).
4. Correia AO, Feitosa PWG, Moreira JL de S, Nogueira SÁR, Fonseca RB, Nobre MEP. Neurological manifestations of COVID-19 and other coronaviruses: A systematic review [Internet]. Vol. 37, *Neurology Psychiatry and Brain Research.* Elsevier GmbH; 2020 [cited 2021 May 29]. p. 27–32. Available from: </pmc/articles/PMC7261450/>
5. Heneka MT, Golenbock D, Latz E, Morgan D, Brown R. Immediate and long-term consequences of COVID-19 infections for the development of neurological disease. *Alzheimer's Res Ther* [Internet]. 2020 Jun 4 [cited 2021 May 29];12(1). Available from: </pmc/articles/PMC7271826/>
6. Widmann CN, Heneka MT. Long-term cerebral consequences of sepsis [Internet]. Vol. 13, *The Lancet Neurology.* Lancet Publishing Group; 2014 [cited 2021 May 29]. p. 630–6. Available from: <https://pubmed.ncbi.nlm.nih.gov/24849863/>
7. Tetz G, Tetz V. SARS-CoV-2 prion-like domains in spike proteins enable higher affinity to ACE2. 2020 Mar 29 [cited 2021 Jun 1]; Available from: [www.preprints.org](http://www.preprints.org)
8. Tian M, Yang J, Li L, Li J, Lei W, Shu X. Vaccine-Associated Neurological Adverse Events: A Case Report and Literature Review. *Curr Pharm Des* [Internet]. 2019 Nov 19 [cited 2021 Apr 28];25(43):4570–8. Available from: <https://pubmed.ncbi.nlm.nih.gov/31742492/>
9. Belay ED. Transmissible spongiform encephalopathies in humans [Internet]. Vol. 53, *Annual Review of Microbiology.* Annu Rev Microbiol; 1999 [cited 2021 Apr 28]. p. 283–314. Available from: <https://pubmed.ncbi.nlm.nih.gov/10547693/>
10. Öz Atalay F, Tolunay Ş, Özgün G, Bekar A, Zarifoğlu M. Creutzfeldt-Jakob Hastalığı:Dört Olgunun Sunumu ve Literatürün Gözden Geçirilmesi. *Turk Patoloji Derg.* 2015;31(2):148–52.
11. Manix M, Kalakoti P, Henry M, Thakur J, Menger R, Guthikonda B, et al. Creutzfeldt-Jakob disease: Updated diagnostic criteria, treatment algorithm, and the utility of brain biopsy. *Neurosurg Focus.* 2015;39(5):1–11.
12. Mahale RR, Javali M, Mehta A, Sharma S, Acharya P, Srinivasa R. A study of clinical profile, radiological and electroencephalographic characteristics of suspected creutzfeldt-jakob disease in a tertiary care centre in south India. *J Neurosci Rural Pract* [Internet]. 2015 Jan 1 [cited 2021 Apr 28];6(1):39–50. Available from: <https://pubmed.ncbi.nlm.nih.gov/25552850/>
13. Diagnostic Criteria I Creutzfeldt-Jakob Disease, Classic (CJD) I Prion Disease I CDC [Internet]. Centers for Disease Control and Prevention. 2018 [cited 2021 May 29]. Available from: <https://www.cdc.gov/prions/cjd/diagnostic-criteria.html>
14. Wieser HG, Schindler K, Zumsteg D. EEG in Creutzfeldt-Jakob disease [Internet]. Vol. 117, *Clinical Neurophysiology.* Clin Neurophysiol; 2006 [cited 2021 Apr 28]. p. 935–51. Available from: <https://pubmed.ncbi.nlm.nih.gov/16442343/>
15. Na DL, Suh CK, Choi SH, Moon HS, Seo DW, Kim SE, et al. Diffusion-weighted magnetic resonance imaging in probable Creutzfeldt- Jakob disease: A clinical-anatomic correlation. *Arch Neurol* [Internet]. 1999 Aug [cited 2021 Apr 28];56(8):951–7. Available from: <https://pubmed.ncbi.nlm.nih.gov/10448800/>