

ORIGINAL ARTICLE

Prenatal maternal depression alters amygdala functional connectivity in 6-month-old infants

A Qiu^{1,2}, TT Anh¹, Y Li¹, H Chen³, A Rifkin-Graboi², BFP Broekman^{2,4}, K Kwek³, S-M Saw⁵, Y-S Chong⁶, PD Gluckman², MV Fortier⁷ and MJ Meaney^{2,8,9}

Prenatal maternal depression is associated with alterations in the neonatal amygdala microstructure, shedding light on the timing for the influence of prenatal maternal depression on the brain structure of the offspring. This study aimed to examine the association between prenatal maternal depressive symptomatology and infant amygdala functional connectivity and to thus establish the neural functional basis for the transgenerational transmission of vulnerability for affective disorders during prenatal development. Twenty-four infants were included in this study with both structural magnetic resonance imaging (MRI) and resting-state functional MRI (fMRI) at 6 months of age. Maternal depression was assessed at 26 weeks of gestation and 3 months after delivery using the Edinburgh Postnatal Depression Scale. Linear regression was used to identify the amygdala functional networks and to examine the associations between prenatal maternal depressive symptoms and amygdala functional connectivity. Our results showed that at 6 months of age, the amygdala is functionally connected to widespread brain regions, forming the emotional regulation, sensory and perceptual, and emotional memory networks. After controlling for postnatal maternal depressive symptoms, infants born to mothers with higher prenatal maternal depressive symptoms showed greater functional connectivity of the amygdala with the left temporal cortex and insula, as well as the bilateral anterior cingulate, medial orbitofrontal and ventromedial prefrontal cortices, which are largely consistent with patterns of connectivity observed in adolescents and adults with major depressive disorder. Our study provides novel evidence that prenatal maternal depressive symptomatology alters the amygdala's functional connectivity in early postnatal life, which reveals that the neuroimaging correlates of the familial transmission of phenotypes associated with maternal mood are apparent in infants at 6 months of age.

Translational Psychiatry (2015) 5, e508; doi:10.1038/tp.2015.3; published online 17 February 2015

INTRODUCTION

Exposure to prenatal maternal depression increases the susceptibility for depression in the offspring^{1,2} and associates with an increase in neurobehavioral,³ cognitive⁴ and socio-emotional problems.⁵ Prenatal maternal depression is also associated with elevated maternal cortisol levels⁶ that, in turn, predict an enlarged amygdala in 7-year-old children.⁷ As increased amygdala volume is associated with depression,^{8–11} these findings appear to reflect the prenatal, transgenerational transmission of individual differences in vulnerability for depression. However, these findings may be confounded by postnatal influences, such as parental care, which is strongly affected by parental mental health.¹² We recently found a significant relation between prenatal maternal depression and the amygdala's microstructure of infants in the imaging study performed shortly after birth.¹³ But, there is still a lack of knowledge on whether the amygdala functions of infants are also influenced by prenatal maternal depression.

The amygdala is a key brain region closely associated with stress reactivity and vulnerability for depressive disorder.¹⁴ Structural magnetic resonance imaging (MRI) studies showed

alterations in the amygdala volume in children, adolescents and adults with major depressive disorder (MDD).^{8–11} Functional MRI (fMRI) studies found the selective involvement of the amygdala in mood disorders, as well as in the processing of emotionally negative information and the accompanying stress responses.^{15,16} Metabolic activity in the amygdala was found to be correlated with negative mood.¹⁷ Increased amygdala activation in response to novelty or threatening faces in children was associated with measures of negative emotionality,^{18,19} which in turn predicted a greater risk for mood disorders.^{20–22} More interestingly, similar findings can also be shown in terms of amygdala functional connectivity. Using resting-state fMRI (rs-fMRI), researchers found that patients with major depression showed altered connectivity of the amygdala with the anterior cingulate,²³ prefrontal gyrus²⁴ and insula.²⁵

In this study, we aimed to investigate the amygdala functional connectivity of 6-month-old infants as a function of prenatal maternal depressive symptoms using rs-fMRI. In line with the literature mentioned above, we expected that the amygdala's functional connectivity with key brain structures regulating

¹Department of Biomedical Engineering and Clinical Imaging Research Center, National University of Singapore, Singapore, Singapore; ²Singapore Institute for Clinical Sciences, Singapore, Singapore; ³KK Women's and Children's Hospital, Duke-National University of Singapore, Singapore, Singapore; ⁴Department of Psychological Medicine, Yong Loo Lin School of Medicine, National University of Singapore, National University Health System, Singapore, Singapore; ⁵Saw Swee Hock School of Public Health, National University of Singapore, Singapore, Singapore; ⁶Department of Obstetrics and Gynaecology, Yong Loo Lin School of Medicine, National University of Singapore, National University Health System, Singapore, Singapore; ⁷Department of Diagnostic and Interventional Imaging, KK Women's and Children's Hospital, Singapore, Singapore; ⁸Ludmer Centre for Neuroinformatics and Mental Health, Douglas Mental Health University Institute, McGill University, Montreal, QC, Canada and ⁹Sackler Program for Epigenetics and Psychobiology, McGill University, Montreal, QC, Canada. Correspondence: Dr A Qiu, Department of Biomedical Engineering, National University of Singapore, 9 Engineering Drive 1, Block EA #03-12, Singapore 117576, Singapore.

E-mail: bieqa@nus.edu.sg

Received 7 July 2014; revised 25 November 2014; accepted 19 December 2014

emotion processes, such as the prefrontal cortex, cingulate and insula, as well as the sensory structures relevant to emotion generation, is a function of prenatal maternal depressive symptoms. We particularly used the rs-fMRI technique to examine amygdala functional networks as it enables a summary of complex patterns of brain functional organization. Moreover, it is free of tasks, imposes a minimal cognitive burden on participants and takes relatively little time in the scanner compared with task fMRI studies. Therefore, it becomes a valuable tool to examine infant brain functional networks²⁶ and provides a unique opportunity to understand the brain functional organization as a function of prenatal maternal depressive symptoms. The results of this study provide, to our knowledge, the first direct link between prenatal maternal depressive symptoms and the amygdala functional networks in infants.

MATERIALS AND METHODS

Subjects

Forty-two infants of mothers who participated in a birth cohort study, GUSTO (Growing Up in Singapore Towards Healthy Outcomes), were recruited for the neuroimaging study at 6 months of age. The GUSTO cohort consisted of pregnant Asian women attending the first trimester antenatal ultrasound scan in a clinic at the National University Hospital and KK Women's and Children's Hospital in Singapore. The parents were Singapore citizens or Permanent Residents of Chinese, Malay or Indian ethnic background. Birth outcome and pregnancy measures were obtained from hospital records. Socioeconomic status (household income) and prenatal exposure to alcohol (regular alcohol drinking) and tobacco (regular smoking, daily exposure to smoking at home and job) were extracted from survey questionnaires conducted as part of a scheduled appointment during pregnancy. The detailed recruitment criteria and measures of the GUSTO cohort were described in Eberhard-Garn *et al.*²⁷ The GUSTO study was approved by the National Healthcare Group Domain Specific Review Board and the Sing Health Centralized Institutional Review Board.

Edinburgh Postnatal Depression Scale

The Edinburgh Postnatal Depression Scale (EPDS) questionnaire was administered to mothers at 26 weeks of pregnancy and at 3 months after delivery and used to quantify maternal prenatal and postnatal levels of depressive symptomatology. The EPDS is a widely used 10-item self-report scale designed as a screening instrument for postnatal depression and has been well validated for use in both prenatal and postnatal depression.^{27–29} In the EPDS, each item is scored on a four-point scale (0–3). The reliability of the EPDS score was 0.82, which was assessed using Cronbach's analysis for our cohort. Higher scores on the EPDS indicate a greater severity of depressive symptoms.

MRI acquisition

Infants underwent MRI scans at 6 months of life using a 1.5-Tesla GE scanner at the Department of Diagnostic and Interventional Imaging of the KK Women's and Children's Hospital. The imaging protocols were (i) fast spin-echo T2-weighted MRI (axial acquisition; TR = 3500 ms; TE = 110 ms; FOV = 256 mm × 256 mm; matrix size = 256 × 256; 50 axial slices with 2.0 mm thickness), (ii) fast spin-echo T2-weighted MRI (coronal acquisition; TR = 3500 ms; TE = 110 ms; FOV = 256 mm × 256 mm; matrix size = 256 × 256; 50 axial slices with 2.0 mm thickness) and (iii) echo planar rs-fMRI (axial acquisition; TR = 2500 ms; TE = 40 ms; FOV = 192 mm × 192 mm; matrix size = 64 × 64; 40 axial slices with 3.0 mm thickness; 120 volumes). The scans were acquired when the subjects were sleeping in the scanner. No sedation was used and precautions were taken to reduce exposure to the MRI scanner noise. A neonatologist was present during each scan. A pulse oximeter was used to monitor heart rate and oxygen saturation through the entirety of the scans.

Amygdala delineation

We manually delineated the amygdala on the image created by averaging the axial and coronal T2-weighted images within individual subjects through a halfway affine transformation.³⁰ This new image had better

signal-to-noise ratio and better spatial resolution than the acquired coronal or axial T2-weighted image alone. The manual tracing of the amygdala was performed on the coronal view of this new image closely following a standard protocol reported elsewhere.³¹ Five subjects' images were manually delineated twice by one rater. The intra-class correlation coefficient was 0.84 for the amygdala of 6-month-old infants.

Amygdala functional connectivity analysis

The rs-fMRI data were first processed with slice timing, motion correction, skull stripping, band-pass filtering (0.01–0.1 Hz) and grand mean scaling of the data. We only included subjects with framewise displacement (head motion characteristics, range from 0.05 to 0.47 in our sample) less than 0.5 as suggested by Power *et al.*³² However, three subjects showed sudden 'jerk-like' head movements at the first three volumes. We manually removed these three volumes to create the new fMRI data sets for these three subjects that satisfied the head motion criteria. Within each subject, the six parameters of the head motion and CSF and white matter signals were regressed out from the fMRI images. Finally, the fMRI images were aligned to the T2-weighted image.

To analyze the amygdala functional networks, the time-series signal averaged across the amygdala was first computed. Pearson's correlation coefficients between the amygdala fMRI mean signal and the fMRI signals of the rest of the brain were subsequently calculated and transformed to 'z-values' using Fisher's z-transformation. The z-map images were finally aligned to the atlas of infant at 6 months on the basis of the nonlinear transformation obtained from the large deformation diffeomorphic metric mapping algorithm.³³

Statistical analysis

Voxel-based analysis was examined to first determine the amygdala functional connectivity networks and then investigate the influences of maternal depression on the amygdala functional connectivity using SPM8. The fMRI z-map images were smoothed with a Gaussian kernel with a full width half maximum of 6 mm. First, regression analysis was applied to the smoothed z-map images to identify the amygdala functional networks with the post-conceptual age on the MRI day (gestational age + days of life since birth to the MRI scan) as a covariate. Second, regression analysis was used to examine the associations between prenatal maternal depression and the amygdala functional networks with the post-conceptual age on the MRI day and postnatal maternal depression as covariates. All statistical results at each voxel were thresholded at the level of significance ($P < 0.01$), the size of each cluster was > 100 voxels with the significance level of each cluster < 0.05 . The statistical results were then corrected for multiple comparisons using false discovery rate.

We further examined whether any other confounding variables, such as household income, birth weight and sex, altered the association between prenatal maternal depression and amygdala functional networks. We first extracted the brain regions with significant associations with prenatal maternal depression and averaged the z-values within each of these brain regions. Regression analysis was subsequently performed with the mean z-value of one brain region as the dependent variable and prenatal maternal depression as the independent variable. The post-conceptual age on the MRI day, postnatal maternal depression and one of the confounding variables were entered as covariates. We repeated this analysis for every brain region and every confounding variable.

RESULTS

Demographics

Among the 42 infants in this study, 15 with missing T2 or fMRI data and 3 with large motion in the fMRI data were excluded. Hence, only 24 subjects were included in this study. All the 24 subjects had gestational age ≥ 35 weeks (range = 35.4–40.2 weeks), birth weight larger than 2000 g (range = 2330–4070 g) and a 5-min APGAR score > 9 (Table 1).

The pairwise correlation between measures of prenatal and postnatal maternal depression scores exceeded 0.5 ($r = 0.663$, $P = 0.002$). Student's *t*-test scores also showed that the magnitude of the maternal depression level was comparable between the assessments at pregnancy and the early postpartum period ($t = 0.236$, $P = 0.816$). Maternal depression did not vary as a

Table 1. Demographics

	Subjects (n = 24)
Gestational age (week), mean (s.d.)	38.60 (1.29)
Postconceptual age on the MRI day (week), mean (s.d.)	66.58 (1.82)
Birth weight (g), mean (s.d.)	3130.17 (380.41)
Sex, male/female	12/12
<i>Ethnicity, (%)</i>	
Chinese	41.7
Malay	45.8
Indian	12.5
Prenatal maternal depression (EPDS), mean (s.d.)	9.13 (4.77)
Postnatal maternal depression (EPDS), mean (s.d.)	9.05 (3.78)
<i>Monthly household income (S\$), %</i>	
≤ 999	9.1
1000 ~ 1999	22.7
2000 ~ 3999	22.7
4000 ~ 5999	27.3
≥ 6000	18.2
Prenatal smoking exposure (n)	1
Prenatal alcohol exposure (n)	0

Abbreviation: EPDS, Edinburgh Postnatal Depression Scale; MRI, magnetic resonance imaging.

Table 2. The amygdala functional networks

Left amygdala	Right amygdala
<i>Emotional regulation network</i>	
L/R insula	L/R insula
L/R anterior cingulate	L/R anterior cingulate
L/R lateral, medial orbitofrontal cortex	L/R lateral, medial orbitofrontal cortex
L/R ventromedial prefrontal cortex	L/R ventromedial prefrontal cortex
L/R dorsolateral prefrontal cortex	L/R dorsolateral prefrontal cortex
L/R ventrolateral prefrontal cortex	L/R ventrolateral prefrontal cortex
<i>Sensory and perceptual systems</i>	
L/R precentral gyrus	L/R precentral gyrus
L/R postcentral gyrus	L/R postcentral gyrus
L/R superior, middle, inferior temporal cortex	L/R superior, middle, inferior temporal cortex
R supramarginal gyrus	L/R supramarginal gyrus
L/R angular gyrus	L angular gyrus
L/R lingual gyrus	L/R lingual gyrus
R cuneus	L/R cuneus
L/R lateral occipital cortex	L/R lateral occipital cortex
L/R thalamus	L/R thalamus
L/R basal ganglia	L/R basal ganglia
L/R midbrain	L/R midbrain
L/R anterior cerebellum	L/R anterior cerebellum
<i>Emotional memory network</i>	
L/R hippocampus	L/R hippocampus
L/R parahippocampus	L/R parahippocampus
L/R entorhinal cortex	L/R entorhinal cortex

Abbreviations: L, left; R, right.

function of infant sex (prenatal: $t=0.720$, $P=0.479$; postnatal: $t=-0.533$, $P=0.601$) or maternal ethnicity (prenatal: $F=2.512$, $P=0.105$; postnatal: $F=0.083$, $P=0.921$). Further examination on the variables listed in Table 1, via Pearson's correlation, revealed that monthly household income was negatively correlated with prenatal ($r=-0.475$, $P=0.026$) but not postnatal maternal depression ($r=-0.167$, $P=0.509$).

Amygdala functional networks

We first identified the amygdala functional networks (Table 2). As shown in Figure 1, both left and right amygdala functionally connected common brain regions forming multiple amygdala networks. These networks included (i) an emotional regulation network that involved the bilateral insula, anterior cingulate cortex (ACC), lateral and medial orbitofrontal cortices, ventromedial, dorsal and ventrolateral prefrontal cortices; (ii) sensory and perceptual systems that comprised the bilateral precentral and postcentral gyri, superior, middle and inferior temporal cortex, lingual gyrus, lateral occipital cortex, thalamus, basal ganglia, midbrain and anterior cerebellum, as well as the right supramarginal gyrus and cuneus, left angular gyrus; (iii) an emotional memory network that consisted of the bilateral hippocampus, parahippocampus and entorhinal cortex. Moreover, the left amygdala sensory and perceptual systems also involved the left angular gyrus, whereas the right amygdala sensory and perceptual systems also included the left supramarginal gyrus and left cuneus.

Our analysis further revealed positive associations between prenatal maternal depression and the left amygdala functional connectivity with multiple regions in the amygdala functional networks identified above (Table 3, Figure 2). Infants born to mothers with higher levels of depressive symptoms during pregnancy showed greater functional connectivity of the left amygdala with (i) the bilateral medial prefrontal cortex (mPFC), including ACC, medial orbitofrontal cortex and ventromedial prefrontal cortex, and left insula in the emotional regulation network; (ii) the left superior, middle and temporal cortex in the sensory and perceptual systems; (iii) the left entorhinal cortex in the emotional memory network. These findings remained significant even after controlling for the post-conceptual age on the MRI day and postnatal maternal depressive symptoms. This

suggests that the above findings were not confounded by postnatal maternal depression. Further examination confirmed that none of the other confounding variables, such as household income, birth weight and sex, altered the aforementioned associations between prenatal maternal depressive symptoms and the left amygdala functional connectivities. We did not find any association between prenatal maternal depressive symptoms and the right amygdala function connectivity.

DISCUSSION

We showed that amygdala functional networks in infancy are similar to those seen in childhood and adulthood, suggesting that the functional connections of the amygdala exist in infancy and persist into later life. Interestingly, independent of postnatal maternal depressive symptoms, prenatal maternal depressive symptoms were positively associated with the left amygdala functional connectivity with the key brain regions involved in the activation and regulation of emotional states. This finding suggests that the developmental origins of neural circuits associated with an increased vulnerability for depression may be apparent in infancy and established as a function of intrauterine maternal influences.

We observed that at 6 months of age the amygdala was functionally connected to a number of brain regions, forming the emotional regulation, sensory and perceptual, and emotional memory networks. These functional connections of the amygdala are well-known anatomical connections in nonhuman primates.³⁴ The high degree of concordance with those functional networks observed in our study, and those seen in children³⁵ and adults³⁶ suggests that these functional connections of the amygdala appear in early life and persist into adulthood. The most consistent

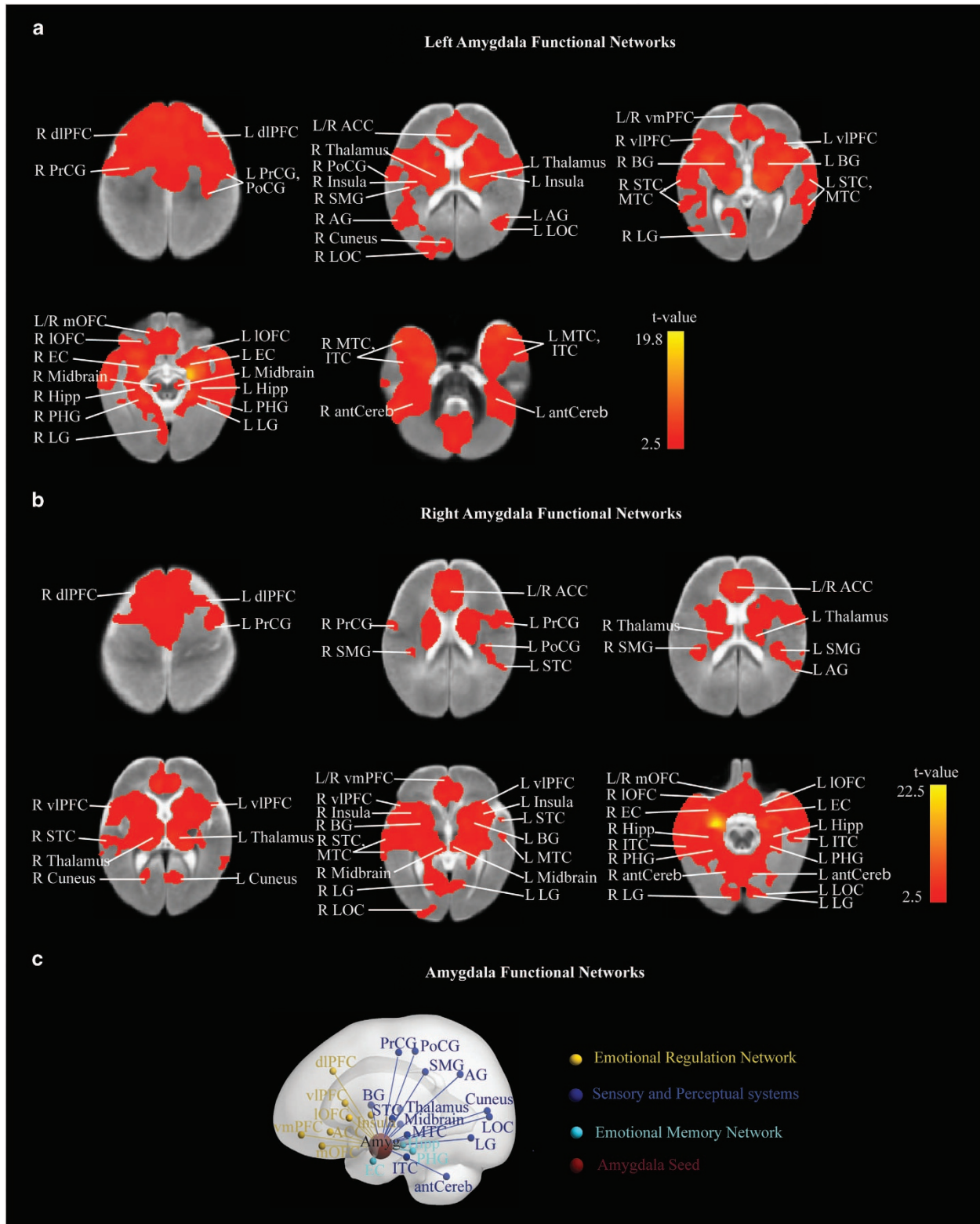


Figure 1. The amygdala functional networks. **(a)** left amygdala functional networks; **(b)** right amygdala functional networks; **(c)** amygdala functional networks. ACC, anterior cingulate cortex; AG, angular gyrus; Amyg, amygdala; antCereb, anterior cerebellum; BG, basal ganglia; dlPFC, dorsolateral prefrontal cortex; EC, entorhinal cortex; Hipp, hippocampus; IOFC, lateral orbitofrontal cortex; ITC, inferior temporal cortex; L, left; LG, lingual gyrus; LOC, lateral occipital cortex; mOFC, medial orbitofrontal cortex; MTC, middle temporal cortex; PoCG, postcentral gyrus; PrCG, precentral gyrus; R, right; SMG, supramarginal gyrus; STC, superior temporal cortex; vIPFC, ventrolateral prefrontal cortex; vmPFC, ventromedial prefrontal cortex.

findings are the functional connections of the amygdala with the prefrontal cortex, including the insula, ACC, orbitofrontal cortex (OFC), ventromedial prefrontal cortex and ventrolateral prefrontal cortex, which provides the basis for the top-down emotional regulation.^{37–39} Moreover, the amygdala functionally connects with multi-modal sensory regions, suggesting the amygdala’s central role in perception and response to fearful stimuli presented in autonomic, somatomotor, visual and auditory modalities, such as the anticipatory arousal and uncertainty,⁴⁰ unpleasant olfactory stimuli,⁴¹ unfamiliar faces⁴² and fearful vocalizations.⁴³ Furthermore, the functional connections of the amygdala and medial temporal lobe emphasize the role of the amygdala in modulating the consolidation of medial temporal lobe-dependent emotional memories.⁴⁴ Hence, even at infancy, the amygdala is positioned for a crucial role in the top-down regulation of emotion through direct modulation of the prefrontal cortex and bottom-up emotional processes, such as emotional perception and encoding affective, motivational and social salience of environmental stimuli, generation of affective state and autonomic responses, and formation of emotional memory and fear conditioning.

Our study showed that prenatal maternal depression alters the infants’ amygdala functional connectivity with specific brain regions involved in both bottom-up and top-down processes of emotion generation and regulation. In the bottom-up network of the amygdala, higher prenatal maternal depressive symptoms were associated with its greater functional connectivity with the temporal cortex and insula, regions that are important for processing fearful facial expressions of emotion. It has been shown that viewing emotional faces increases the coupling between the fusiform and amygdala.⁴⁵ Interestingly, a resting-state functional connectivity analysis recently identified links the insula to the middle and inferior temporal cortex as well as the ACC.⁴⁶ The insula also shares extensive reciprocal connections

with the amygdala and is implicated in the ability to differentiate positive versus negative emotion processing and hence making judgments about emotions on the basis of facial expression and conveying the representation of aversive sensory information to the amygdala.^{47,48} Elevated responses to the presentation of fearful or sad facial expression in the amygdala, insula and temporal cortex associate with depression, possibly mediated via rich connections with amygdala circuitry.^{49,50} These emotional processing biases in depression have been suggested to be important in the underlying etiology of this disorder.³⁶ Furthermore, aberrant functional connectivity of the amygdala with the insula and temporal cortex is also found in association with depression.^{25,51,52} Thus, with evidence of a greater risk for depression in the offspring born to depressed mothers, our findings of increased amygdala-temporal/insular connectivity in infants born to mothers with greater prenatal maternal depressive symptoms suggest that the amygdala bottom-up network could be the neural origin for the transgenerational transmission of vulnerability for depression.

In the top-down network of the amygdala, higher prenatal maternal depressive symptoms were associated with its greater functional connectivity with the mPFC, which is in line with studies of amygdala–mPFC connectivity in adolescents with internalizing symptoms⁵³ and early-onset MDD,⁵⁴ as well as in adults with MDD.⁵⁵ The ventromedial prefrontal cortex and OFC connect to and receive inputs from the amygdala and temporal cortex and then, in turn, send signals from these regions as well as the cingulate. The ACC has strong connections with limbic structures, such as the amygdala and OFC. Moreover, the amygdala–PFC connections have been consistently observed in task-based³⁷ and rs-fMRI.³⁶ Hence, the top-down network of the amygdala is believed to provide the basis for emotion regulation processes.

Interestingly, our results showed only the left amygdala functional connectivity with the mPFC in the association with prenatal maternal depressive symptoms. This lateralized pattern of the amygdala was supported by evidence that top-down responses may modulate only the left amygdala.²⁵ Although the literature regarding the laterality of amygdala dysfunction in MDD is mixed,^{25,56} our results may emphasize the leftward laterality of the amygdala because the left hemisphere has the more rapid growth of gray and white matters than the right during infancy.⁵⁷ Hence, the left amygdala and its connections may be more vulnerable to prenatal influences. Taken together, the altered amygdala–mPFC connectivity in infants born to mothers with increased prenatal maternal depressive symptoms is similar to that which is observed in patients with MDD, reflecting the neural basis for the familial transmission of phenotypes associated with mood disorders.

Our findings also support growing evidence suggesting that the origins of many brain abnormalities in neuropsychiatric and neurodevelopmental disorders can be traced back to the intrauterine period of life, when the fetus is influenced by

Table 3. Prenatal maternal depression in relation with the amygdala functional networks

Left amygdala	Right amygdala
<i>Emotional regulation network</i>	
L insula	NS
L/R anterior cingulate	
L/R medial orbitofrontal cortex	
L/R ventromedial prefrontal cortex	
<i>Sensory and perceptual systems</i>	
L superior, middle, inferior temporal cortex	
<i>Emotional memory network</i>	
L entorhinal cortex	

Abbreviations: L, left; NS, no significance; R, right.

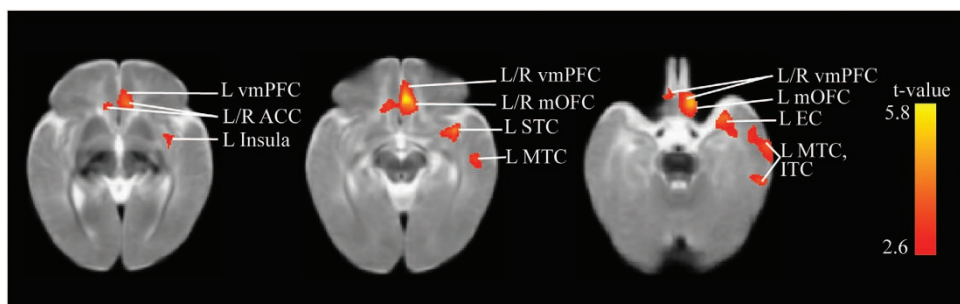


Figure 2. The association between prenatal maternal depression and amygdala functional networks. ACC, anterior cingulate cortex; EC, entorhinal cortex; ITC, inferior temporal cortex; L, left; mOFC, medial orbitofrontal cortex; MTC, middle temporal cortex; R, right; STC, superior temporal cortex; vmPFC, ventromedial prefrontal cortex.

environmental conditions during sensitive periods of cellular proliferation, differentiation and maturation to produce structural and functional changes in the brain. In animal models, changes in brain morphology have been observed in offspring of mothers exposed to prenatal stress. Significantly expanded dimensions of the lateral nucleus of the amygdala were found in prenatally stressed offspring.⁵⁸ Reduced spine densities and dendritic length of pyramidal neurons in the dorsal ACC and OFC have also been reported in rats born to prenatally stressed mothers.⁵⁹ Depressed mothers exhibit increased cortisol level during pregnancy. Converging evidence from a variety of species suggests that cortisol exerts multiple effects on the brain, which include altering neurotransmitter functioning,⁶⁰ affecting the development of oligodendrocytes and the glia cells that manufacture myelin sheets in the central nervous system,⁶¹ and influencing glucocorticoid receptor rich regions such as the amygdala, the activation of which may further alter neurotransmitter function.⁶² In humans, elevated prenatal cortisol level was associated with a larger amygdala volume in children.⁷ Moreover, prenatal maternal depression was associated with difficult temperament in infancy⁶³ even when controlling for postnatal mood.⁶⁴ Such fetal programming enhances traits such as threat sensitivity and prepares the fetus to develop within a harsh postnatal environment, while influencing children's mental health trajectories.^{65,66} It is also important to note that prospective studies underscore the importance of individual differences in stress reactivity as predictors of the risk for depression.^{67,68}

Our study has several limitations. First, the sample size in this study is relatively small, although comparable to infant imaging studies. In addition, our study only included an Asian population. Hence, the results from this study require replication and generalization to other populations. Moreover, considering both scientific importance and subjects burden, our study only assessed postnatal maternal depressive symptoms at 3 months and 12 months but not at 6 months after delivery when the infant brain imaging was conducted. Though additional measurements may have allowed for a better understanding of postnatal maternal effects on infant brain function at 6 months of age, our sample showed a high correlation of maternal depression scales at 3 months and 12 months after delivery ($r=0.544$, $P < 0.001$).

In conclusion, our findings provide novel evidence that prenatal maternal depressive symptoms alter the amygdala functional connectivity in early postnatal life, suggesting that the neural correlates of the familial transmission of phenotypes associated with MDD are apparent in infants at 6 months of age. Our findings suggest the fetal programming of the transgenerational transmission of maternal mental well-being to the offspring.

CONFLICT OF INTEREST

The authors declare no conflict of interest.

ACKNOWLEDGMENTS

We thank Dr Li Kong for the initial analysis. We thank the GUSTO study group and all clinical and home visit staff involved. The voluntary participation of all the participants is greatly appreciated. The GUSTO study group includes Pratibha Agarwal, Arijit Biswas, Choon Looi Bong, Shirong Cai, Jerry Kok Yen Chan, Yiong Huak Chan, Cornelia Yin Ing Chee, Yin Bun Cheung, Audrey Chia, Amutha Chinnadurai, Chai Kiat Chng, Mary Foong-Fong Chong, Shang Chee Chong, Mei Chien Chua, Chun Ming Ding, Eric Andrew Finkelstein, Doris Fok, Keith M. Godfrey, Anne Eng Neo Goh, Yam Thiam Daniel Goh, Joshua J Gooley, Wee Meng Han, Mark Hanson, Christiani Jayekumar Henry, Joanna D Holbrook, Chin-Ying Hsu, Hazel Inskip, Jeevesh Kapur, Ivy Yee-Man Lau, Bee Wah Lee, Yung Seng Lee, Ngee Lek, Sok Bee Lim, Yen-Ling Low, Iliana Magiati, Lourdes Mary Daniel, Cheryl Ngo, Krishnamoorthy Naiduvaje, Wei Wei Pang, Boon Long Quah, Victor Samuel Rajadurai, Mary Rauff, Salome A Rebello, Jenny L Richmond, Lynette Pei-Chi Shek, Allan Sheppard, Borys Shuter, Leher Singh, Shu-E Soh, Walter Stunkel, Lin Lin Su, Kok Hian Tan, Oon Hoe Teoh, Mya Thway Tint, Hugo P

S van Bever, Rob M van Dam, Inez Bik Yun Wong, PC Wong, Fabian Yap, George Seow Heong Yeo. This study is supported by National Medical Research Council (NMRC; NMRC/TCR/012-NUHS/2014 and NMRC/CBRG/0039/2013), the Young Investigator Award at the National University of Singapore (NUSYIA FY10 P07) and the Singapore Ministry of Education Academic Research Fund Tier 2 (MOE2012-T2-2-130).

REFERENCES

- Pearson RM, Evans J, Kounali D, Lewis G, Heron J, Ramchandani PG et al. Maternal depression during pregnancy and the postnatal period: risks and possible mechanisms for offspring depression at age 18 years. *JAMA Psychiatry* 2013; **70**: 1312–1319.
- Pawlbly S, Hay DF, Sharp D, Waters CS, O'Keane V. Antenatal depression predicts depression in adolescent offspring: prospective longitudinal community-based study. *J Affect Disord* 2009; **113**: 236–243.
- MIAN Al. Depression in pregnancy and the postpartum period: balancing adverse effects of untreated illness with treatment risks. *J Psychiatr Pract* 2005; **11**: 389–396.
- Sohr-Preston SL, Scaramella LV. Implications of timing of maternal depressive symptoms for early cognitive and language development. *Clin Child Family Psychol Rev* 2006; **9**: 65–83.
- Lundy B, Field T, Pickens J. Newborns of mothers with depressive symptoms are less expressive. *Infant Behav Dev* 1996; **19**: 419–424.
- Davis EP, Glynn LM, Schetter CD, Hobel C, Chicz-Demet A, Sandman CA. Prenatal exposure to maternal depression and cortisol influences infant temperament. *J Am Acad Child Adolesc Psychiatry* 2007; **46**: 737–746.
- Buss C, Davis EP, Shahbaba B, Pruessner JC, Head K, Sandman CA. Maternal cortisol over the course of pregnancy and subsequent child amygdala and hippocampus volumes and affective problems. *Proc Natl Acad Sci USA* 2012; **109**: E1312–E1319.
- Lupien SJ, Parent S, Evans AC, Tremblay RE, Zelazo PD, Corbo V et al. Larger amygdala but no change in hippocampal volume in 10-year-old children exposed to maternal depressive symptomatology since birth. *Proc Natl Acad Sci USA* 2011; **108**: 14324–14329.
- Malykhin NV, Carter R, Hegadoren KM, Seres P, Coupland NJ. Fronto-limbic volumetric changes in major depressive disorder. *J Affect Disord* 2012; **136**: 1104–1113.
- Holmes AJ, Lee PH, Hollinshead MO, Bakst L, Roffman JL, Smoller JW et al. Individual differences in amygdala-medial prefrontal anatomy link negative affect, impaired social functioning, and polygenic depression risk. *J Neurosci* 2012; **32**: 18087–18100.
- van Eijndhoven P, van Wingen G, van Oijen K, Rijpkema M, Goraj B, Jan Verkes R et al. Amygdala volume marks the acute state in the early course of depression. *Biol Psychiatry* 2009; **65**: 812–818.
- Fleming AS, Flett GL, Ruble DN, Shaul DL. Postpartum adjustment in 1st-time mothers—relations between mood, maternal attitudes, and mother infant interactions. *Dev Psychol* 1988; **24**: 71–81.
- Rifkin-Graboi A, Bai J, Chen H, Hameed WB, Sim LW, Tint MT et al. Prenatal maternal depression associates with microstructure of right amygdala in neonates at birth. *Biol Psychiatry* 2013; **74**: 837–844.
- Price JL, Drevets WC. Neurocircuitry of mood disorders. *Neuropsychopharmacology* 2009; **35**: 192–216.
- Hamilton JP, Gotlib IH. Neural substrates of increased memory sensitivity for negative stimuli in major depression. *Biol Psychiatry* 2008; **63**: 1155–1162.
- Pruessner JC, Dedovic K, Khalili-Mahani N, Engert V, Pruessner M, Buss C et al. Deactivation of the limbic system during acute psychosocial stress: evidence from positron emission tomography and functional magnetic resonance imaging studies. *Biol Psychiatry* 2008; **63**: 234–240.
- Abercrombie HC, Schaefer SM, Larson CL, Oakes TR, Lindgren KA, Holden JE et al. Metabolic rate in the right amygdala predicts negative affect in depressed patients. *Neuroreport* 1998; **9**: 3301–3307.
- Perez-Edgar K, Roberson-Nay R, Hardin MG, Poeth K, Guyer AE, Nelson EE et al. Attention alters neural responses to evocative faces in behaviorally inhibited adolescents. *Neuroimage* 2007; **35**: 1538–1546.
- Gaffrey MS, Barch DM, Singer J, Shenoy R, Luby JL. Disrupted amygdala reactivity in depressed 4- to 6-year-old children. *J Am Acad Child Adolesc Psychiatry* 2013; **52**: 737–746.
- Caspi A, Moffitt TE, Newman DL, Silva PA. Behavioral observations at age 3 years predict adult psychiatric disorders. Longitudinal evidence from a birth cohort. *Arch Gen Psychiatry* 1996; **53**: 1033–1039.
- Cote SM, Boivin M, Liu X, Nagin DS, Zoccolillo M, Tremblay RE. Depression and anxiety symptoms: onset, developmental course and risk factors during early childhood. *J Child Psychol Psychiatry* 2009; **50**: 1201–1208.

- 22 van Marle HJ, Hermans EJ, Qin S, Fernandez G. From specificity to sensitivity: how acute stress affects amygdala processing of biologically salient stimuli. *Biol Psychiatry* 2009; **66**: 649–655.
- 23 Connolly CG, Wu J, Ho TC, Hoeft F, Wolkowitz O, Eisendrath S et al. Resting-state functional connectivity of subgenual anterior cingulate cortex in depressed adolescents. *Biol Psychiatry* 2013; **74**: 898–907.
- 24 Kong L, Chen K, Tang Y, Wu F, Driesen N, Womer F et al. Functional connectivity between the amygdala and prefrontal cortex in medication-naïve individuals with major depressive disorder. *J Psychiatr Neurosci* 2013; **38**: 417.
- 25 Ramasubbu R, Konduru N, Cortese F, Bray S, Gaxiola-Valdez I, Goodyear B. Reduced intrinsic connectivity of amygdala in adults with major depressive disorder. *Front Psychiatry* 2014; **5**: 17.
- 26 Franssón P, Skjöld B, Horsch S, Nordell A, Blennow M, Lagercrantz H et al. Resting-state networks in the infant brain. *Proc Natl Acad Sci USA* 2007; **104**: 15531–15536.
- 27 Eberhard-Gran M, Eskild A, Tambs K, Opjordsmoen S, Samuelsen SO. Review of validation studies of the Edinburgh Postnatal Depression Scale. *Acta Psychiatr Scand* 2001; **104**: 243–249.
- 28 Bergink V, Kooistra L, Lambregtse-van den Berg MP, Wijnen H, Bunevicius R, van Baar A et al. Validation of the Edinburgh Depression Scale during pregnancy. *J Psychosom Res* 2011; **70**: 385–389.
- 29 Murray D, Cox JL. Screening for depression during pregnancy with the Edinburgh Depression Scale (EPDS). *J Reprod Infant Psychol* 1990; **8**: 99–107.
- 30 Smith SM. Fast robust automated brain extraction. *Hum Brain Mapp* 2002; **17**: 143–155.
- 31 Griffiths P, Morris J, Larroche J-C. Atlas of Fetal and Postnatal Brain MR. Elsevier Health Sciences, USA, 2009.
- 32 Power JD, Barnes KA, Snyder AZ, Schlaggar BL, Petersen SE. Spurious but systematic correlations in functional connectivity MRI networks arise from subject motion. *Neuroimage* 2012; **59**: 2142–2154.
- 33 Miller MI, Qiu A. The emerging discipline of computational functional anatomy. *Neuroimage* 2009; **45**: 16–39.
- 34 Amaral DG, Price JL. Amygdalo-cortical projections in the monkey (Macaca fascicularis). *J Comp Neurol* 1984; **230**: 465–496.
- 35 Qin S, Young CB, Duan X, Chen T, Supekar K, Menon V. Amygdala subregional structure and intrinsic functional connectivity predicts individual differences in anxiety during early childhood. *Biol Psychiatry* 2013; **75**: 892–900.
- 36 Roy AK, Shehzad Z, Margulies DS, Kelly A, Uddin LQ, Gotimer K et al. Functional connectivity of the human amygdala using resting state fMRI. *Neuroimage* 2009; **45**: 614–626.
- 37 Stein JL, Wiedholz LM, Bassett DS, Weinberger DR, Zink CF, Mattay VS et al. A validated network of effective amygdala connectivity. *Neuroimage* 2007; **36**: 736–745.
- 38 Hariiri AR, Mattay VS, Tessitore A, Fera F, Weinberger DR. Neocortical modulation of the amygdala response to fearful stimuli. *Biol Psychiatry* 2003; **53**: 494–501.
- 39 Ochsner KN, Ray RD, Cooper JC, Robertson ER, Chopra S, Gabrieli JD et al. For better or for worse: neural systems supporting the cognitive down-and-up-regulation of negative emotion. *Neuroimage* 2004; **23**: 483–499.
- 40 Critchley HD, Mathias CJ, Dolan RJ. Neural activity in the human brain relating to uncertainty and arousal during anticipation. *Neuron* 2001; **29**: 537–545.
- 41 Zald DH, Pardo JV. Emotion, olfaction, and the human amygdala: amygdala activation during aversive olfactory stimulation. *Proc Natl Acad Sci USA* 1997; **94**: 4119–4124.
- 42 Dubois S, Rossion B, Schiltz C, Bodart JM, Michel C, Bruyer R et al. Effect of familiarity on the processing of human faces. *Neuroimage* 1999; **9**: 278–289.
- 43 Phillips ML, Young AW, Scott SK, Calder AJ, Andrew C, Giampietro V et al. Neural responses to facial and vocal expressions of fear and disgust. *Proc Biol Sci* 1998; **265**: 1809–1817.
- 44 Dolcos F, LaBar KS, Cabeza R. Interaction between the amygdala and the medial temporal lobe memory system predicts better memory for emotional events. *Neuron* 2004; **42**: 855–863.
- 45 Fairhall SL, Ishai A. Effective connectivity within the distributed cortical network for face perception. *Cerebr Cortex* 2007; **17**: 2400–2406.
- 46 Cauda F, D'Agata F, Sacco K, Duca S, Geminiani G, Vercelli A. Functional connectivity of the insula in the resting brain. *Neuroimage* 2011; **55**: 8–23.
- 47 Anand A, Li Y, Wang Y, Lowe MJ, Dzemidzic M. Resting state corticolimbic connectivity abnormalities in unmedicated bipolar disorder and unipolar depression. *Psychiatry Res* 2009; **171**: 189–198.
- 48 Alexopoulos GS, Hoptman MJ, Yuen G, Kanellopoulos D, Seirup JK, Lim KO et al. Functional connectivity in apathy of late-life depression: a preliminary study. *J Affect Disord* 2013; **149**: 398–405.
- 49 Surguladze S, Brammer MJ, Keedwell P, Giampietro V, Young AW, Travis MJ et al. A differential pattern of neural response toward sad versus happy facial expressions in major depressive disorder. *Biol Psychiatry* 2005; **57**: 201–209.
- 50 Chan SW, Norbury R, Goodwin GM, Harmer CJ. Risk for depression and neural responses to fearful facial expressions of emotion. *Br J Psychiatry* 2009; **194**: 139–145.
- 51 Tahmasian M, Knight DC, Manoliu A, Schwerthoffer D, Scherr M, Meng C et al. Aberrant intrinsic connectivity of hippocampus and amygdala overlap in the fronto-insular and dorsomedial-prefrontal cortex in major depressive disorder. *Front Hum Neurosci* 2013; **7**: 639.
- 52 Zeng LL, Shen H, Liu L, Wang L, Li B, Fang P et al. Identifying major depression using whole-brain functional connectivity: a multivariate pattern analysis. *Brain* 2012; **135**(Pt 5): 1498–1507.
- 53 Burghy CA, Stodola DE, Ruttle PL, Molloy EK, Armstrong JM, Oler JA et al. Developmental pathways to amygdala-prefrontal function and internalizing symptoms in adolescence. *Nat Neurosci* 2012; **15**: 1736–1741.
- 54 Perlman G, Simmons AN, Wu J, Hahn KS, Tapert SF, Max JE et al. Amygdala response and functional connectivity during emotion regulation: a study of 14 depressed adolescents. *J Affect Disord* 2012; **139**: 75–84.
- 55 Erk S, Mikschl A, Stier S, Ciaramidaro A, Gapp V, Weber B et al. Acute and sustained effects of cognitive emotion regulation in major depression. *J Neurosci* 2010; **30**: 15726–15734.
- 56 Drevets WC, Price JL, Furey ML. Brain structural and functional abnormalities in mood disorders: implications for neurocircuitry models of depression. *Brain Struct Funct* 2008; **213**: 93–118.
- 57 Gilmore JH, Lin W, Prastawa MW, Looney CB, Vetsa YSK, Knickmeyer RC et al. Regional gray matter growth, sexual dimorphism, and cerebral asymmetry in the neonatal brain. *J Neurosci* 2007; **27**: 1255–1260.
- 58 Salm AK, Pavelko M, Krouse EM, Webster W, Kraszpulski M, Birkle DL. Lateral amygdaloid nucleus expansion in adult rats is associated with exposure to prenatal stress. *Brain Res Dev Brain Res* 2004; **148**: 159–167.
- 59 Murmu MS, Salomon S, Biala Y, Weinstock M, Braun K, Bock J. Changes of spine density and dendritic complexity in the prefrontal cortex in offspring of mothers exposed to stress during pregnancy. *Eur J Neurosci* 2006; **24**: 1477–1487.
- 60 Wyrwoll CS, Holmes MC. Prenatal excess glucocorticoid exposure and adult affective disorders: a role for serotonergic and catecholamine pathways. *Neuroendocrinology* 2011; **95**: 47–55.
- 61 Byravan S, Campagnoni AT. Serum factors and hydrocortisone influence the synthesis of myelin basic proteins in mouse brain primary cultures. *Int J Dev Neurosci* 1994; **12**: 343–351.
- 62 Herman JP, Ostrander MM, Mueller NK, Figueiredo H. Limbic system mechanisms of stress regulation: hypothalamo-pituitary-adrenocortical axis. *Prog Neuropsychopharmacol Biol Psychiatry* 2005; **29**: 1201–1213.
- 63 Field T, Diego M, Hernandez-Reif M. Prenatal depression effects and interventions: a review. *Infant Behav Dev* 2010; **33**: 409–418.
- 64 Huizink AC, de Medina PGR, Mulder EJJ, Visser GHA, Buitelaar JK. Psychological measures of prenatal stress as predictors of infant temperament. *J Am Acad Child Adolesc Psychiatry* 2002; **41**: 1078–1085.
- 65 Seckl JR, Holmes MC. Mechanisms of disease: glucocorticoids, their placental metabolism and fetal 'programming' of adult pathophysiology. *Nat Clin Pract Endocrinol Metab* 2007; **3**: 479–488.
- 66 Diorio J, Meaney MJ. Maternal programming of defensive responses through sustained effects on gene expression. *J Psychiatry Neurosci* 2007; **32**: 275–284.
- 67 Wichers M, Geschwind N, Jacobs N, Kenis G, Peeters F, Derom C et al. Transition from stress sensitivity to a depressive state: longitudinal twin study. *Br J Psychiatry* 2009; **195**: 498–503.
- 68 Widom CS, DuMont K, Czaja SJ. A prospective investigation of major depressive disorder and comorbidity in abused and neglected children grown up. *Arch Gen Psychiatry* 2007; **64**: 49–56.



This work is licensed under a Creative Commons Attribution-NonCommercial-ShareAlike 4.0 International License. The images or other third party material in this article are included in the article's Creative Commons license, unless indicated otherwise in the credit line; if the material is not included under the Creative Commons license, users will need to obtain permission from the license holder to reproduce the material. To view a copy of this license, visit <http://creativecommons.org/licenses/by-nc-sa/4.0/>