

# Broca's Region Subserves Imagery of Motion: A Combined Cytoarchitectonic and fMRI Study

Ferdinand Binkofski<sup>1</sup>, Katrin Amunts<sup>2</sup>, Klaus Martin Stephan<sup>1</sup>,  
Stefan Posse<sup>3</sup>, Thorsten Schormann<sup>2</sup>, Hans-Joachim Freund<sup>1</sup>,  
Karl Zilles<sup>2,3</sup>, and Rüdiger J. Seitz<sup>1\*</sup>

<sup>1</sup>Department of Neurology, Heinrich-Heine-University Düsseldorf, Düsseldorf, Germany

<sup>2</sup>C. and O. Vogt Institute of Brain Research and Institute of Neuroanatomy,  
Heinrich-Heine-University Düsseldorf, Düsseldorf, Germany

<sup>3</sup>Institute of Medicine, Research Center Jülich, Jülich, Germany

---

**Abstract:** Broca's region in the dominant cerebral hemisphere is known to mediate the production of language but also contributes to comprehension. Here, we report the differential participation of Broca's region in imagery of motion in humans. Healthy volunteers were studied with functional magnetic resonance imaging (fMRI) while they imagined movement trajectories following different instructions. Imagery of right-hand finger movements induced a cortical activation pattern including dorsal and ventral portions of the premotor cortex, frontal medial wall areas, and cortical areas lining the intraparietal sulcus in both cerebral hemispheres. Imagery of movement observation and of a moving target specifically activated the opercular portion of the inferior frontal cortex. A left-hemispheric dominance was found for egocentric movements and a right-hemispheric dominance for movement characteristics in space. To precisely localize these inferior frontal activations, the fMRI data were coregistered with cytoarchitectonic maps of Broca's areas 44 and 45 in a common reference space. It was found that the activation areas in the opercular portion of the inferior frontal cortex were localized to area 44 of Broca's region. These activations of area 44 can be interpreted to possibly demonstrate the location of the human analogue to the so-called mirror neurones found in inferior frontal cortex of nonhuman primates. We suggest that area 44 mediates higher-order forelimb movement control resembling the neuronal mechanisms subserving speech. *Hum. Brain Mapping* 11:273–285, 2000. © 2000 Wiley-Liss, Inc.

**Key words:** fMRI; cytoarchitectonics; motor imagery; premotor cortex; parietal cortex; movement control

---

## INTRODUCTION

Since the seminal case description by Broca [1861], it has been well known that damage to the inferior fron-

tal cortex severely disrupts language production [Mesulam, 1990; Liberman, 1996]. The advent of neuroimaging studies led to the insight that the posterior part of the inferior frontal cortex actively participates in language production [Petersen et al., 1988; Wise et al., 1991; Zatorre et al., 1992; Swaab et al., 1995; Kim et al., 1997]. More recently its involvement in visual and auditory language comprehension and syntactic as well as phonological processing has been advocated [Pugh et al., 1996; Stromswold et al., 1996; Zatorre et al., 1996; Friederici et al., 1997; Chee et al., 1999].

---

Contract grant sponsor: Sonderforschungsbereich 194.

\*Correspondence to: Dr. Rüdiger J. Seitz, MD, Department of Neurology, Heinrich-Heine-University Düsseldorf, Moorenstrasse 5, D-40225 Düsseldorf, Germany.

E-mail: seitz@neurologie.uni-duesseldorf.de

Received for publication 17 August 1999; accepted 30 August 2000

Because Broca's region occurred only in human brain evolution, its functional role cannot be analyzed by analogous experiments in nonhuman primates. Broca's region consists of area 44 and 45, of which area 44 exhibits a possible homology to the inferior premotor cortex in the monkey brain as was repeatedly pointed out in cytoarchitectonic studies [von Bonin and Bailey, 1947; Petrides and Pandya, 1994; Galaburda and Pandya, 1982; Preuss et al., 1995]. More recently, physiological evidence was obtained in the macaque suggesting that area F5 in the inferior premotor cortex at a comparable location to that of Broca's region contains neurons that match observed actions with executed actions of the orofacial region and the upper limb [Gallese et al., 1996; Rizzolatti et al., 1997]. Accordingly, Broca's region might not only be critical for speech but may play a more general role for motor control by interfacing external information about motion with motor acts.

Support for this view was derived from neuroimaging studies showing inferior frontal activations during finger movement sequence learning, and imagery of joy stick movements and object grasping [Seitz and Roland, 1992; Decety et al., 1994; Stephan et al., 1995; Grafton et al., 1996a, 1996b]. Recently, we demonstrated by functional magnetic resonance imaging (fMRI) that manipulation of complex objects engaged the ventral premotor cortex, while recognition and naming of the objects markedly activated the opercular and the triangular part of the inferior frontal cortex [Binkofski et al., 1999]. Spatial normalization of the activation data and localization in stereotactic coordinates provided means to anatomically characterize these activation areas. However, in all these studies it was impossible to decide which cytoarchitectonic part of Broca's region participated in movement control, as the stereotactic space of Talairach and Tournoux [1988] is based on macroscopic aspects of the human brain that has no definite relation to the cytoarchitec-

tonic parcellation of the constituting cortical areas [Rademacher et al., 1993; Roland and Zilles, 1994].

Here, we explored which portion of Broca's region possesses motor representations of the dominant hand. Because motor representations are rehearsed by mentation even in the absence of movement, their specific implementation loci can be identified in the human brain by neuroimaging techniques [Jeannerod, 1994; Berthoz, 1996]. To this end, we designed a goal-directed motor task that involved a spatially complex movement and could readily be studied given the technical constraints of fMRI scanning. Thus, the starting point was an index finger movement employing the maximal degree of freedom of controlled action. To identify the representations related to movement control, we adopted motor imagery tasks that had either a somatosensory or visual focus or involved observation of motion. While the former tasks were expected to engage premotor and parietal cortical areas, the latter tasks aimed at identifying inferior frontal premotor cortical areas related to processing of the concept of movement or abstract motion. To specifically examine which portion of the inferior frontal cortex was involved, fMRI activation data were integrated with cytoarchitectonic information of Broca's region (i.e., cytoarchitectonic areas 44 and 45) [Brodmann, 1909] in a common spatial format [Roland and Zilles, 1994]. The cytoarchitectonic information was derived from 10 postmortem brains providing a probabilistic reference frame to which functional activations were registered. In contrast, the Talairach atlas [1988] is based on a brain ascribing Brodmann areas to brain anatomy without a microscopical assessment of the cytoarchitectonic parcellation of the cortical areas. By our multimodal image coregistration approach we were able to show that imagery of abstract motion was associated with specific activation in cytoarchitectonic area 44.

## METHODS

### Subjects

Six right-handed male subjects (age range: 25–40 years) with no history of neurological illness participated in this study. All of them gave an informed consent. The study was approved by the Ethics Committee of the Heinrich-Heine-University Düsseldorf. Right-handedness was assessed by the Edinburgh Inventory [Oldfield, 1971]. They had a mean score of visual imagery of  $21.8 \pm 2.1$  (SD) as assessed by the MRT-A [Peters et al., 1995].

### Abbreviations

AIP	anterior intraparietal area
Cing	cingulate cortex
DP	dorsal parietal cortex
fMRI	functional magnetic resonance imaging
M1/S1	sensorimotor cortex
PMC	premotor cortex
SG	imagery of somatosensory guided movements
SMA	supplementary motor area
SO	imagery of movement observation
TO	imagery of moving target
VG	imagery of visually guided movements

### Behavioral Tasks

Subjects were lying comfortably in the scanner with their arms relaxed. The scanner room was darkened. EMG recordings from the first dorsal interosseus muscle were performed to monitor muscle activity. The subjects were required to perform seven different task conditions:

#### **Movement 1 (SG): Somatosensory guided movement**

The subjects were instructed to produce with their outstretched right index finger the infinite movement of a horizontal double circle. They were required to produce the movement as accurately as possible, while focusing on the somatosensory sensation of moving the finger. Their eyes were closed. Prior to scanning the subjects were trained by a metronome and asked to keep the 0.5 Hz pace during scanning. The control period was rest with relaxing the arms and the eyes closed.

#### **Imagery 1 (SG)**

During imagery of somatosensory guided movement the subjects were asked to imagine moving their right index finger in double circle form at a pace of 0.5 Hz while having their hands and arms relaxed. Again, they were required to focus on the imagined somatosensory sensation of moving the finger, while having their eyes closed. During the control period they were asked to avoid motor imagery.

#### **Movement 2 (VG): Visually guided movement**

The double circle was presented by a light point moving on a screen with a pace of 0.5 Hz. The screen was positioned at the foot end of the scanner bed and the target was presented to the subject through a mirror placed above the subject's eyes. Subjects were required to attend to the light point and to pursue the target with their right index finger as accurately as possible. They could not see their moving hands during the activation period. In the control period the subjects viewed the light point in the center of the screen having their arms relaxed.

#### **Imagery 2 (VG)**

During imagery of visually guided movement the subjects were asked to imagine the movement of the right index finger following the target while having their eyes closed. No target was presented. During the

control period they were asked to avoid any imagery having their eyes closed.

#### **Imagery 3 (SO)**

During imagery of self-observation, the subjects were asked to imagine observing themselves moving the right index finger following the target, while they were lying in the fMRI scanner. The instruction was to have the eyes closed and to view the scene from an appropriate distant perspective and to not move. During the control period the subjects were asked to avoid any imagery and to have their eyes closed.

#### **Imagery 4 (TO)**

During imagery of target observation the subjects were asked to imagine the light point moving on the screen with their eyes closed. They were required to imagine the path of the moving target but not to move their own fingers. During the control period they were asked to avoid any imagery having their eyes closed.

In a final condition, the subjects were required to perform index tapping on the thumb of the right hand at 0.5 Hz with their eyes closed. This condition served to subtract movement-related activation from the movement conditions. After scanning, the subjects were asked whether they experienced imagery of the conditions and whether they were able to differentiate between the imagery conditions. They all reported that they were able to direct their attention toward the imagery goal during the active periods and to disregard all imageries during the control periods. Eye movements were not recorded because a reliable method for eye movement recordings was not available.

### Functional Imaging

Functional magnetic resonance imaging (fMRI) of cerebral blood oxygen level-dependent signal changes was performed on a Siemens 1.5T scanner with a gradient booster and standard rf coil as described in detail elsewhere [Binkofski et al., 1998, 1999]. Sixteen contiguous horizontal slices parallel to the intercommissural line with a thickness of 4.4 mm were acquired every 3 sec using echoplanar imaging sequences (TE = 66 ms,  $\gamma = 90^\circ$ ). The field of view was  $200 \times 200$  pixels in  $64 \times 64$  matrix. In-plane resolution of the image slices was  $3.12 \times 3.12$  mm. The 16 image slices covered the dorsal part of the brain above the internal capsule. Each experiment consisted of 50 images representing five alternating control-active pairs

allowing 10 images for each epoch. In addition, anatomical imaging was performed using volumetric 3D T1-weighted high-contrast sequences.

Imaging data were analyzed off-line using SPM96 software of the Leopold Müller Functional Imaging Laboratory, London. First, images were corrected for head movements, signal intensity variation, normalized spatially into stereotactic space and smoothed with an 8-mm isotropic Gaussian kernel. Thereafter, group analysis of the data was performed. Significance was assessed using the delayed boxcar reference function of the SPM96 software. Pixels were considered significant when they had a correlation of their time series with the reference function exceeding a Z-score of 2.66 (corresponding to a corrected  $P < 0.01$ ). They were localized in stereotactic space [Talairach and Tournoux, 1988]. In addition, activated areas were required to reach a cluster threshold of 0.05 (corrected for resolution elements). For visualisation, color-coded quantitative maps of positive contrasts were superimposed onto the T1-weighted canonical SPM templates.

### Cytoarchitectonic Mapping

The areas 44 and 45 were mapped [Amunts et al., 1997, 1999] in serial histological sections (20  $\mu\text{m}$ ) stained for cell bodies of 10 human brains [Merker, 1983]. Both areas were identified using criteria of Kononova [Kononova, 1949]. However, the exact locations of the borders of areas 44 and 45 were defined by an observer-independent method. This method requires the estimation of the fraction of cortical volume occupied by nerve cell bodies by measuring the grey level index from the border between layers I/II to the cortex/white-matter border [Schleicher and Zilles, 1990]. Multivariate statistics were applied for testing differences in the laminar pattern of the grey level index between neighboring areas (Mahalanobis distance and subsequent Hotelling  $T^2$  test). Data on the extent of both areas on the histological sections was transferred to the digitized images of the sections and 3D reconstructed. Corrections of deformations caused by the histological technique were performed, and brain volumes were transformed to the spatial standard reference format [Roland and Zilles, 1994; Schormann et al., 1996]. The centers of gravity of areas 44 and 45 were identified in the right and left hemisphere of each brain studied and localized in stereotactic space [Talairach and Tournoux, 1988]. The mean Cartesian distances between areas 44 and 45 were calculated and evaluated for each hemisphere by t-test. Also, the spatially normalized, high-resolution MR

images of the subjects were transformed into the spatial standard reference format of the European Computerized Human Brain Database (ECHBD) [Roland and Zilles, 1994]. Thereby, transformation parameters were created which were then used to transform the activation maps into the spatial standard reference format. Finally, the superimposition of corresponding cytoarchitectonic areas of the individual brains in the ECHBD format was used for the estimation of inter-subject variability in the extent of the areas.

## RESULTS

### Movement Trajectories

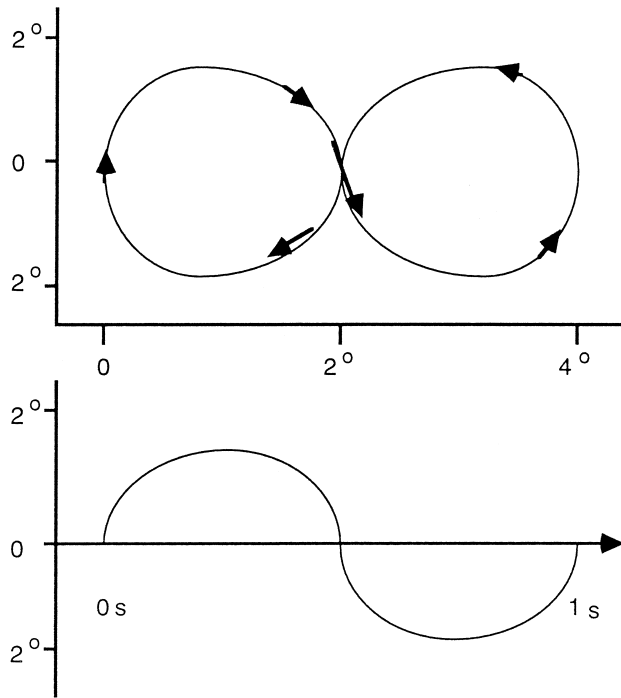
Participants imagined or executed the movement trajectories with their right index finger under changing conditions. The trajectory was an infinite horizontal double circle that had to be performed within 2 sec (Fig. 1). In the movement conditions the subjects had to generate the movements by themselves without external pacing; however, prior to each scan they were acquainted with a 0.5 Hz metronome pacing. Electromyographic recordings ascertained that there was no muscle activity in the small hand muscles during the imagery conditions.

### Somatosensory Guided Finger Movements

During self-generated movements under the attentive focus of somatosensory guidance compared with rest (Movement 1) activations occurred in the left sensorimotor cortex, bilateral in the premotor cortex, the supplementary motor area, and cingulate cortex, and in the cortex lining the intraparietal sulcus (Fig. 2, Table I). Compared with simple thumb-index finger tapping movements, the activations in the more dorsal parts of the premotor cortex and in the anterior parietal cortex of both hemispheres were significant (Table I). Imagery of these self-generated movements (Imagery 1) compared with rest also involved activations bilateral in the dorsal portion of the premotor cortex, in the supplementary motor area, in the left cingulate, and the cortex lining the left intraparietal sulcus (Fig. 2, Table I). The activations in the left cingulate and in the intraparietal sulcus closely correspond to the activation pattern related to imagery of graphomotor trajectories as reported recently [Seitz et al., 1997].

### Visually Guided Finger Movements

During self-generated movements under visual guidance (Movement 2) activations occurred in the left



**Figure 1.**

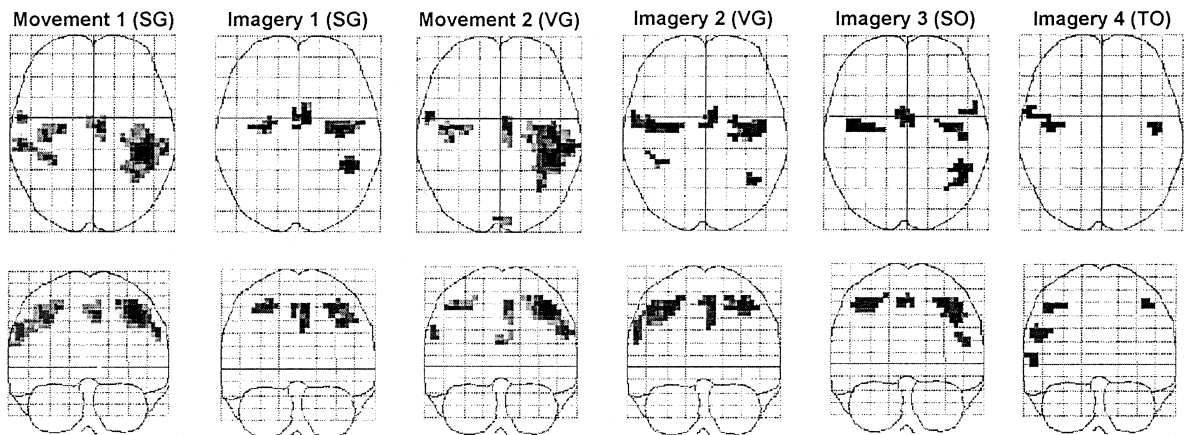
Motion trajectory. The double circle displayed on the screen during visually guided finger movements occupied 4° of the visual field of the subject. Performance of the motor and imagery tasks was paced to 0.5 Hz according to prescanning training.

sensorimotor cortex, bilateral in the premotor cortex, the left supplementary motor area, the left cingulate cortex, and in the cortex lining the left intraparietal sulcus (Fig. 2, Table I). Compared with simple thumb-

index finger tapping movements, the activations in the premotor cortex and in the anterior parietal cortex of left hemisphere were significant (Table I). Imagery of these visually guided movements compared with rest (Imagery 2) involved activations bilateral in the dorsal portion of the premotor cortex, in the supplementary motor area, and bilateral in the cortex lining the intraparietal sulcus (Fig. 2, Table I). This activation occurred in a more posterior location of the intraparietal sulcus than in Imagery 1.

### Imagery of Abstract Movements

During imagery of movement observation compared with rest (Imagery 3), activations occurred bilateral in the premotor cortex, the supplementary motor area, the cingulate, and in areas of cortex lining the left intraparietal sulcus being as extensive as in Imagery 1 and 2 together (Table II, Fig 2). Furthermore, this type of imagery involving the egocentric view from an observer's perspective was accompanied by an activation of the opercular part of the left inferior frontal cortex (Fig. 2). During imagery of a moving target compared with rest (Imagery 4), only few activation areas in the premotor cortex occurred including an activated area in a homologue location in the opercular part of the right inferior frontal cortex (Table II, Fig. 2). However, during this imagery condition of external motion there was no activation in the frontal mesial wall areas or of the parietal cortex (Table II). The activations in the opercular parts of the inferior frontal cortex were specific for the mental processing of ab-



**Figure 2.**

guided movement. Imagery 3 (SO): Imagery of self-observation. Imagery 4 (TO): Imagery of target observation. In all conditions the subjects had their eyes closed except for Movement 3 (VG) and the corresponding control state when the subjects viewed the target on the screen. Right in the images is left in the subjects.

guided movement. Imagery 3 (SO): Imagery of self-observation. Imagery 4 (TO): Imagery of target observation. In all conditions the subjects had their eyes closed except for Movement 3 (VG) and the corresponding control state when the subjects viewed the target on the screen. Right in the images is left in the subjects.

**TABLE I. Activations in execution and imagery of finger movement trajectories**

Area	Stereotactic coordinates (x, y, z in mm)	Somatosensory guided movement	Imagery of somatosensory guided movement	Visually guided movement	Imagery of visually guided movement
L M1/S1	-44, -32, 46	7.75		6.66	
R PMC					
Dorsal	39, -9, 49	4.75*	5.08	4.48	4.55
Ventral	59, 2, 27	4.72*		3.74*	3.79
Opercular	56, 8, 6				
L PMC					
Dorsal	-38, -10, 50	5.76*	4.50	5.52*	5.09
Opercular	-56, 8, 16				
R SMA	4, 0, 50	3.59	3.61		3.05
L SMA	-5, -4, 50	5.21	4.93	4.17	4.29
R Cing	8, 12, 36				
L Cing	-5, -8, 38		4.88	3.10	
R aIP	38, -38, 44	4.82*			4.55
L aIP	-40, -40, 40	4.20*	4.21	4.12*	
L pIP	-40, -56, 52	4.10*		3.32*	4.06
R DP	12, -76, 52				3.64

The maximal Z-scores of the activations compared with rest are given for each activated area in stereotactic space (Talairach and Tournoux, 1988). During execution of the visual guided movement and the corresponding control condition the subjects had their eyes open. M1/S1: Sensorimotor cortex, PMC: lateral premotor cortex, SMA: supplementary motor area, Cing: cingulate cortex, aIP: anterior parietal cortex, pIP: posterior parietal cortex, DP: dorsal parietal cortex. Asterisk indicates significant activation compared to simple thumb-index tapping ( $P < 0.05$  corrected).

stract movement characteristics that became evident from the direct comparison with imagery of visually guided finger movements (Table II). Moreover, the right-left asymmetry was substantiated by the direct comparison of movement imagery from an observer's perspective and imagery of an externally moving target (Table II).

### Common and Different Activations

Compared with rest, the premotor cortex was activated bilateral in the dorsal portions in all movement and imagery conditions (Tables I, II). By contrast, the right ventral and the opercular activations differed between conditions. Like the activations in the opercular part of the inferior frontal cortex, the ventral premotor areas were activated on the left side in imagery of movement observation (Imagery 3), while the right ventral premotor activation occurred in imagery of a moving target (Imagery 4). At the mesial surface of the frontal cortex there was a bilateral activation in the conditions concerned with movement of body parts (Fig. 2, Table I, II). During the two movement conditions these activations most probably included the supplementary motor area, while during imagery of finger movements (Imagery 1, 2, and 3), the activa-

tion was more extended and included also the anterior cingulate. In contrast, there was no activation of the frontal medial wall areas during imagery of the external moving target (Fig. 2). In all imagery conditions the sensorimotor cortex showed no significant signal changes compared with rest. This contrasted to the activation of left sensorimotor cortex during the two finger movement conditions (Table I). The activations in the posterior parietal cortex were more pronounced in the left than in the right cerebral hemisphere (Fig. 2, Table I). They were located in a more anterior position around the anterior intraparietal sulcus during execution and imagery of self generated movements (Movement 1 and Imagery 1) and in a more posterior position during execution and imagery of visually guided movements (Movement 2 and Imagery 2). Both areas were activated during imagery of movement observation (Imagery 3). In contrast, no parietal activations occurred during imagery of the moving target (Imagery 4, Table II).

### Cytoarchitectonic Identification

The fMRI activation maps were realigned with maps of cytoarchitectonic area 44 in a common reference space [Roland and Zilles, 1994]. Localization of

**TABLE II. Activations in imagery of motion**

Area	Stereotactic coordinates	Imagery of movement observation	Imagery of moving target
R PMC			
Dorsal	39, -9, 49	4.11	4.02
Ventral	59, 2, 27		3.36*
Opercular	56, 8, 6		3.79*
L PMC			
Dorsal	-38, -10, 50	4.40	3.20
Ventral	-56, 4, 36	4.40*	
Opercular	-56, 8, 16	4.04*	
R SMA	4, 0, 50	4.27	
L SMA	-5, -4, 50	4.40	
R Cing	8, 12, 36	3.20	
L Cing	-5, -8, 38	3.12	
R aIP	38, -38, 44		
L aIP	-40, -40, 40	3.40	
L pIP	-40, -56, 52	3.40*	

The maximal Z-scores of the activations compared with rest are given for each activated area in stereotactic space (Talairach and Tournoux, 1988). PMC: lateral premotor cortex, SMA: supplementary motor area, Cing: cingulate cortex, aIP: anterior parietal cortex, pIP: posterior parietal cortex indicates significant activation ( $P < 0.05$  corrected) compared to imagery of visually guided finger movements (Imagery 2 VG) as well as in direct comparison to imagery of movement observation (Imagery 3 SO) and imagery of moving target (Imagery 4 TO), respectively.

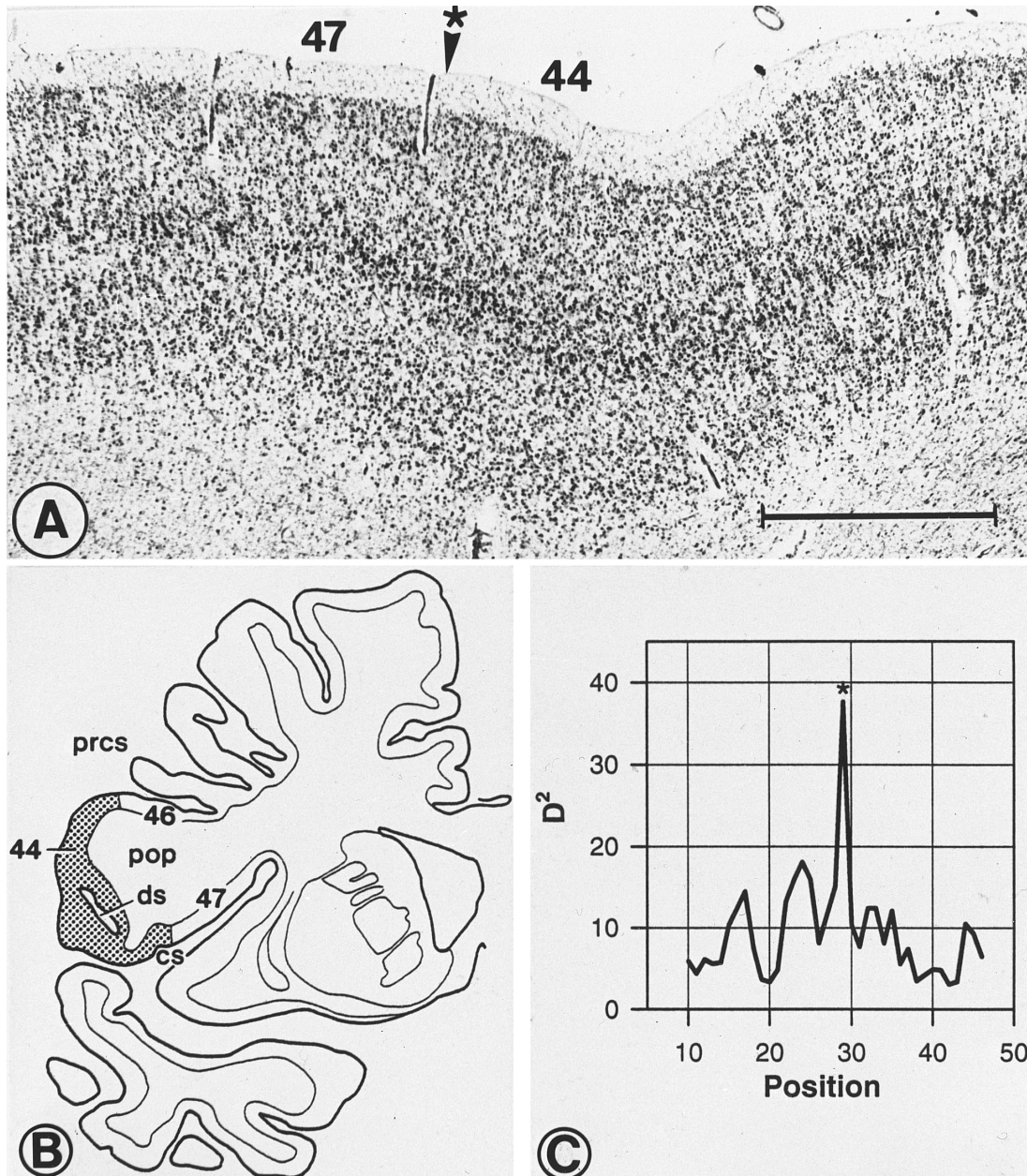
area 44 and identification of its cytoarchitectonic characteristics as determined by cortical grey level measurements are shown in Figure 3. The Nissl stained cortex showed a cytoarchitectonic border to adjacent areas such as areas 45 and 47, and 6. The peaks in the profiles of the grey matter levels marked the borders between adjacent cytoarchitectonic areas. Spatial standardization allowed us to compare the spatial extent and location of areas 44 and 45 in the brains studied. It became apparent that the centers of gravity of areas 44 and 45 were different in location in either hemisphere (Table III). In both hemispheres area 45 was significantly ( $P < 0.005$ ) more rostral than area 44. The coregistration with the fMRI data revealed that area 44 in the frontal opercular cortex occurred in an almost mirror-like location in the left and right hemisphere, respectively (Fig. 4). This figure shows also the anatomical overlap of the inferior frontal activation area with area 44. This functional-anatomic area of overlap is marked in pink (Fig. 4). It is evident that the activated area did not map to ventral area 6 of premotor cortex but to area 44 of Broca's region. Comparing the centers of gravity of the opercular activations and of the spatial extent of area 44, it could be shown that the

activation centered some 3 mm caudal to area 44, while area 45 was more than 15 mm rostral to area 44 (Tables II and III). The data were supported by the analysis of the mean area of functional-anatomic overlap of the activation areas and cytoarchitectonic area 44. It was apparent that at a 50% isocontour level of cytoarchitectonic area 44 there was a 45% overlap with the activation area in Imagery 3 (SO) and a 67% overlap in Imagery 4 (TO).

## DISCUSSION

### The Role of Area 44 for Imagery of Motion

In this study we have shown that the posterior, opercular part of the human inferior frontal cortex became specifically engaged during imagery of abstract movement. Imagery of abstract movement referred to the two conditions in which movement had to be imagined from a third party's perspective. In one condition the task was imagery of one's own movement (Imagery 3), while in the other task it was the imagery of a moving target (Imagery 4). The observation that both of these tasks activated the inferior frontal cortex corresponds to the activations of the opercular frontal cortex reported recently in relation to mental identification of limb orientation and gestures, motor imagery [Decety et al., 1994; Bonda et al., 1995; Parsons et al., 1995; Grafton et al., 1996; Decety et al., 1997] and during object manipulation [Binkofski et al., 1999]. Because there is profound interindividual variability of the location and spatial extent of the pars opercularis of the human inferior frontal cortex as well as of the cytoarchitectonic areas 44 and 45 [Amunts et al., 1999; Tomaiuolo et al., 1999], it remained unresolved in these studies to which cytoarchitectonic loci these activations belong. The new finding of our study is that these most ventral activations were located in area 44 in either hemisphere as demonstrated with spatially aligned cytoarchitectonic maps (Fig. 4). Moreover, we showed that the center of gravity of area 44 was significantly caudal to area 45 (Table III) and rostral to lower area 6 of premotor cortex. We suggest that these opercular activations in humans may correspond to neuronal activations related to action perception and recognition as reported for a set of neurones in the ventral premotor cortex of macaques [Jeannerod et al., 1995; Rizzolatti et al., 1996]. Interestingly, in our study the inferior frontal cortex was not activated by imagery of finger movements but of more derived concepts of motion. In analogy to a lack of activation in premotor cortex in less as compared with more demanding conditions [Binkofski et al., 1999],



**Figure 3.**

Cytoarchitectonic identification and localisation of area 44. (a) Nissl stained cortex of area 44, arrow indicates cytoarchitectonic border to area 47. (b) Localization of area 44 in the inferior frontal cortex in a coronal section of one human brain; prcs = precentral

sulcus; ds = diagonal sulcus; cs = central sulcus; pop = pars opercularis of inferior frontal gyrus. (c) Profile of grey matter levels with peak indicative of border between areas 44 and 47.

imagery of the finger movement trajectories might have been a too simple task for the subjects being not sufficient to activate Broca's region.

A further important finding is our observation of hemispheric asymmetry of this activation depending on the context of mental processing. During imagery of one's own limb motion, from an observer's perspec-

tive there was left-hemispheric activation of area 44, whereas during imagery of spatial target motion in extrapersonal space, significant activation of the right area 44 became apparent. The latter observation corresponds to a recent finding by Vallar et al. [1999] who reported right inferior frontal activation when subjects were required to indicate the midsagittal plane of a



**TABLE III. Localization of cytoarchitectonic areas 44 and 45 in Talairach space**

Area 44 right			Area 45 right			Area 44 left			Area 45 left		
x	y	z	x	y	z	x	y	z	x	y	z
42.5	11.6	19.9	45.1	28.7	18.9	-42.5	11.6	19.9	-42.7	26.1	17.0
(3.1)	(6.9)	(4.5)	(2.1)	(3.1)	(3.6)	(3.1)	(6.8)	(4.5)	(2.1)	(6.9)	(5)

Mean stereotactic coordinates (mm  $\pm$  SD) of the centres of gravity of the cytoarchitectonic areas in mm. On the right side area 45 is 16 mm and on the left side 18 mm rostral to area 44 ( $P < 0.005$ ).

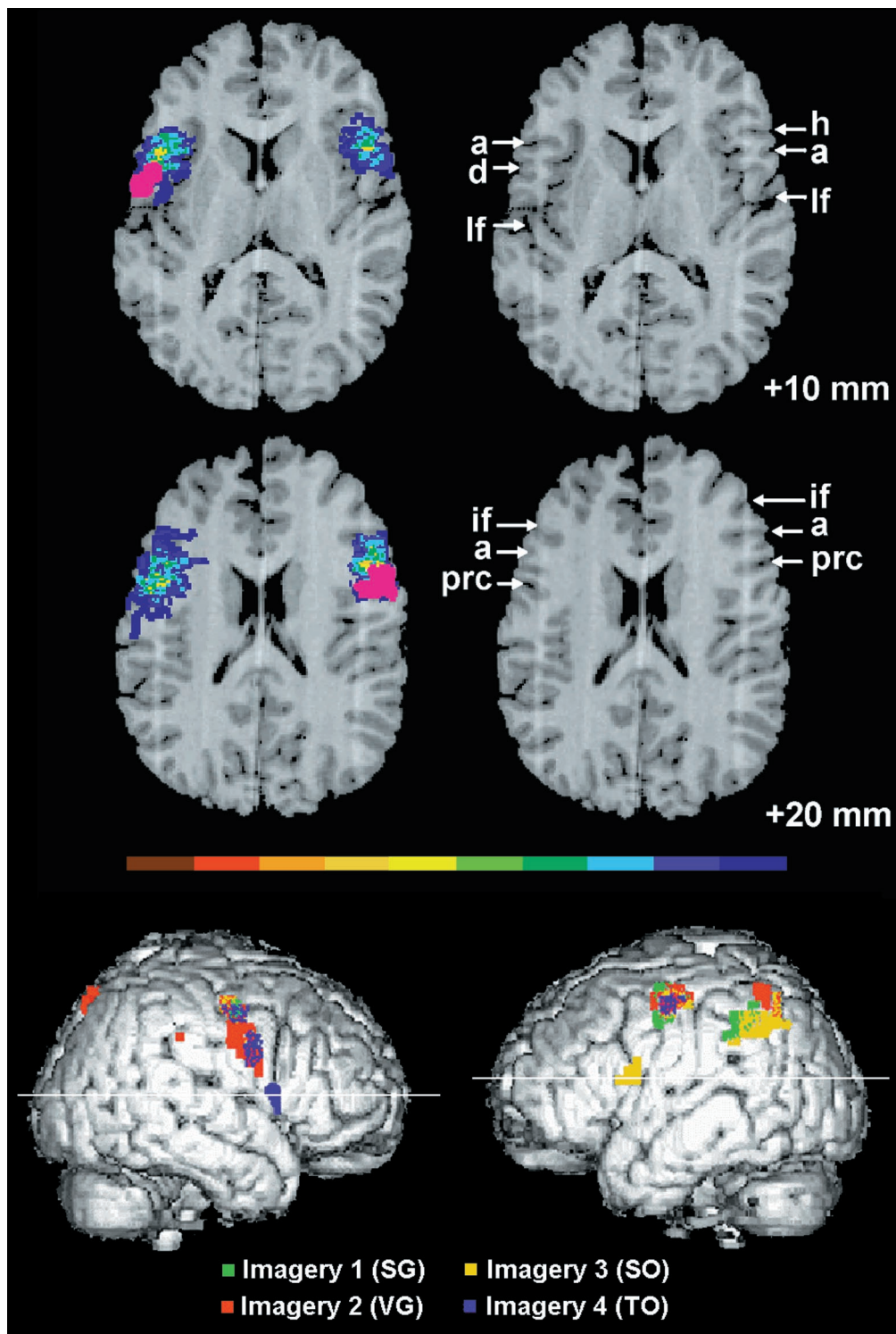
moving target. Activation of the inferior frontal cortex and of Broca's area has so far been shown during language comprehension and production [Petersen et al., 1988; Wise et al., 1991; Zatorre et al., 1992; Swaab et al., 1995; Buckner et al., 1996; Pugh et al., 1996; Stromswold et al., 1996; Zatorre et al., 1996; Friederici et al., 1997; Kim et al., 1997]. Electrical stimulation of Broca's area interferes with language production [Ojemann, 1993]. Thus, Broca's area is critical for speech production, but it also has receptive capacities that can be subjected to acoustic learning [Schäffler et al., 1993; Merzenich et al., 1996; Bookheimer et al., 1997]. The right hemisphere homologue was shown to be critically involved in explicit motor sequence learning and associative motor learning [Seitz et al., 1992; Rauch et al., 1995; Hazeltine et al., 1997]. Similarly, overt and covert production of gestures was shown to activate the right hemispheric inferior frontal cortex [Bonda et al., 1995; Parsons et al., 1995; Decety et al., 1994, 1997]. Therefore, these data support the view that the left hemispheric activation of Broca's region reflected "pragmatic" motor processing, while the right hemispheric activation of Broca's homologue was related to explicit motor processing of motion.

Here, we propose a more general view on these frontal opercular areas. In the monkey there is a large distal hand movement representation in the corresponding rostralmost part of ventral premotor cortex [Rizzolatti et al., 1981; Kurata and Tanji, 1986; Rizzolatti et al., 1988; Wise, 1991; Hepp-Reymond et al., 1994]. Some of the neurons in this so-called area F5 discharge during motor acts and in response to visual presentation of macrogeometric objects provided that these are congruent with the type of prehension coded by the recorded neurone [Gallese et al., 1996; Murata et al., 1997; Rizzolatti et al., 1988]. We argue that area 44 in the human frontal opercular cortex is important for the execution, recognition, and imagery of skilled forelimb movements. For comparison, using the same fMRI-cytoarchitectonic coregistration approach, it was found that area 45 seems to be related to processing of more abstract information inclusive of working mem-

ory [Amunts et al., 1997]. Under the premise that human area 44 accommodates mirror-neurons, area 44 appears suited to mediate the individual's interaction with other subjects by subserving the understanding of other people's motor acts and the generation of responsive motor acts by the individual [Rizzolatti et al., 1997]. These movements are usually communicative gestures or articulatory synergies conveying linguistic information. It is unclear, whether motor imagery and recognition of motion as such involve silent speech. In our experiments, however, the task requirements involved information processing related to forelimb movements but no naming or language production. It is therefore unlikely that silent speech was engaged in this experiment.

#### Area 44 as Part of a Motor Network

The participation of other premotor areas during motor imagery clearly supports the view that the human premotor cortex comprises different subareas as similarly demonstrated in the monkey [Rizzolatti et al., 1988; Tanji 1994]. At the cerebral convexity, the dorsolateral subareas were almost symmetrically distributed in the cerebral hemispheres not only during imagery of abstract motion but also during execution and imagery of movements guided by somatosensory or visual control. These data correspond to similar activation areas during trajectorial movements [Grafton et al., 1996a; Seitz et al., 1997]. Most likely they are related to the performance of sensory-instructed movements [diPellegrino and Wise, 1993], which has been shown to be specifically impaired in patients with lesions of premotor cortex [Halsband and Freund, 1990]. Due to the tight anatomical connections with the parietal lobe, the more dorsal subareas probably receive input from the superior posterior parietal cortex, whereas the more ventral parts probably receive input from the anterior inferior parietal cortex [Luppino et al., 1991; Geyer et al., 1998]. Evidence from microelectrodes recordings in primates and from neuroimaging studies in humans suggests



**Figure 4.**

Intermodal integration of activation and cytoarchitectonic areas on MRI. Superimposition of the inferior frontal activation area (pink) onto cytoarchitectonic area 44: upper row, 67% overlap with mean cytoarchitectonic area during imagery of the moving target, middle row, 45% overlap during imagery of movement observation. Activations compared with rest. Right in the image corresponds to left in the subjects. The degree of spatial overlap of cytoarchitectonic area 44 among the postmortem brains is color coded according to the color bar (1 brain = blue, 10

brains = brown). a = ascending branch of the lateral fissure; h = horizontal branch of the lateral fissure; prc = precentral sulcus; d = diagonal sulcus; lf = lateral fissure; if = inferior frontal sulcus; levels 10 and 20 mm dorsal to the intercommissural line. Lower row, localization of the activated areas on the lateral views of both cerebral hemispheres related to imagery of movement with somatosensory guidance (Imagery 1 SG), visual guidance (Imagery 2 VG), movement observation (Imagery 3 SO), and of the moving target (Imagery 4 TO).

that attentive processing of motor-related information is mediated by the cortex lining the intraparietal sulcus and the middle and dorsal parts of the premotor cortex [Jeannerod et al., 1995; Seitz et al., 1997; Corbetta et al., 1998]. Notably, these dorsal and ventral premotor activations occurred in locations that are engaged also by oculomotor tasks [Luna et al., 1998; Heide et al., 1999] reflecting the close association to eye movements and, possibly, the direction of attention to the tasks demands.

The cortex along the anterior and posterior part of the intraparietal sulcus participated differentially in motor imagery. There was a left hemispheric dominance particularly in the anterior part that has been shown to be critically involved also in somatosensory and visually guided grasping, as well as pointing and reaching [Faillenot et al., 1997; Lacquaniti et al., 1997; Binkofski et al., 1998]. These observations accord with observations in nonhuman primates showing that neurons in the cortex lining the anterior part of the intraparietal sulcus discharge also during object holding and manipulation [Sakata et al., 1992; Jeannerod et al., 1995]. In contrast, the more posterior portions of the parietal cortex are engaged during visuomotor transformations, matching of visually presented objects, and retrieval of learned finger movement sequences [Faillenot et al., 1997; Seitz et al., 1997; Sakai et al., 1998]. No activations were observed in the superior parietal cortex or in the precuneus, which have been shown to become activated during the performance of complicated spatial arm movements and finger movements [Seitz and Roland, 1992; Grafton et al., 1992]. The specific activations in the cortex lining the intraparietal sulcus could implicate involvement related to the generation of the body scheme.

The activations in frontomesial cortex occurred in a region that probably correspond to the SMA and the ventrally adjacent cingulate motor areas [Shima et al., 1991; Matelli et al., 1991]. These areas were only engaged in relation to internal, body-centered motor coding irrespective of sole mental movement processing or real movement execution. This corresponded to similar electrophysiological and neuroimaging findings in nonhuman primates humans and to data on movement initiation and selection [Deiber et al., 1991; Tanji, 1994; Stephan et al., 1995; Jahanshahi et al., 1995; MacKinnon et al., 1996]. The activation of the right anterior cingulate gyrus during imagery of movement observation may be related to divided attention to different sensory cues [Pardo et al., 1990]. Thus, although no network analysis was performed, our data show that activation of area 44 is part of a large-scale network subserving action.

In contrast to the active finger movement conditions, no activations were present in the motor cortex during the imagery conditions. Although discrete activity changes were reported to occur in motor cortex during motor imagery [Porro et al., 1996; Roth et al., 1996; Parsons and Fox, 1997], our negative findings based on omnibus statistics are in good agreement to previous neuroimaging studies on motor imagery [Seitz et al., 1997; Stephan et al., 1995]. Thus, our data accord with the hypothesis that movement representations are maintained in the brain in absence of movement execution [Jeannerod, 1994; Berthoz, 1996]. Further, in neither condition did we observe activations in the visual motion area MT [Watson et al., 1993; Tootell et al., 1995; Goebel et al., 1998], which might be due to the fact that by scanning 16 consecutive axial planes we did not sample information from this lower part of the brain. Taken together, our data suggest that the representations concerned with interactive aspects of human movement control with the external world seem to be localized in the frontal opercular cortex. In that context, cytoarchitectonic area 44 seems to subserve the recognition of abstract motor behavior that is relevant for communication [Liberman, 1996].

## ACKNOWLEDGMENTS

The authors thank Professor G. Rizzolatti, Director of the Institute of Physiology, University of Parma, Italy, and Professor W. Levelt, Director of the Max-Planck-Institute, Nijmegen, The Netherlands, for their helpful comments on an earlier version of this manuscript.

## REFERENCES

- Amunts K, Schleicher A, Schormann T, Bürgel U, Mohlberg H, Uylings, H.B.M., Zilles, K (1997): The cytoarchitecture of Broca's regions and its variability. *Neuroimage* 5:S353.
- Amunts K, Schleicher A, Bürgel U, Mohlberg H, Uylings HBM, Zilles K (1999): Broca's region re-visited: Cytoarchitecture and intersubject variability. *J Comp Neurol* 412:319-341.
- Berthoz A (1996): The role of inhibition in the hierarchical gating of executed and imagined movements. *Brain Res Cogn Brain Res* 3:101-113.
- Binkofski F, Dohle C, Posse S, Stephan KM, Hefter H, Seitz RJ, Freund H-J (1998): Human anterior intraparietal area subserves prehension. A combined lesion and functional MRI activation study. *Neurology* 50:1253-1259.
- Binkofski F, Buccino G, Posse S, Seitz RJ, Rizzolatti G, Freund H-J (1999): A fronto-parietal circuit for object manipulation in man. Evidence from an fMRI-study. *Eur J Neurosci* 11:3276-3286.
- Bonda E, Petrides M, Frey S, Evans A (1995): Neural correlates of mental transformations of the body-in-space. *Proc Natl Acad Sci U S A* 92:11180-11184.

- Bookheimer SY, Zeffiro TA, Blaxton T, Malow BA, Gaillard WD, Sato S, Kufta C, Fedio P, Theodore WH (1997): A direct comparison of PET activation and electrocortical stimulation mapping for language localization. *Neurology* 48:1056–1065.
- Brodmann K (1909): Vergleichende Lokalisationslehre der Grosshirnrinde. Johann Ambrosius Barth, p 130–139.
- Buckner RL, Raichle ME, Miezin FM, Petersen SE (1996): Functional anatomic studies of memory retrieval for auditory words and visual pictures. *J Neurosci* 16:6219–6235.
- Chee MWL, O'Craven KM, Bergida R, Rosen BR, Savoy RL (1999): Auditory and visual word processing studied with fMRI. *Hum Brain Mapp* 7:15–28.
- Corbetta M, Akbudak E, Conturo TE, Snyder AZ, Ollinger JM, Drury HA, Linenweber MR, Petersen SE, Raichle ME, van Essen DC, Shulman GL (1997): A common network of functional areas for attention and eye movements. *Neuron* 21:761–773.
- Decety J, Perani D, Jeannerod M, Bettinardi V, Tadard B, Woods R, Mazziotta JC, Fazio F (1994): Mapping motor representations with positron emission tomography. *Nature* 371:600–602.
- Decety J, Grezes J, Costes N, Perani D, Jeannerod M, Procyk E, Grassi F, Fazio F (1997): Brain activity during observation of actions. Influence of action content and subject's strategy. *Brain* 120:1763–1777.
- Deiber M-P, Passingham RE, Colebatch JG, Friston KJ, Nixon PD, Frackowiak RSJ (1991): Cortical areas and the selection of movement: a study with positron emission tomography. *Exp Brain Res* 84:393–402.
- diPellegrino G, Wise SP (1993): Visuospatial versus visuomotor activity in the premotor and prefrontal cortex of a primate. *J Neurosci* 13:1227–1243.
- Faillenot I, Toni I, Decety J, Grégoire MC, Jeannerod M (1997): Visual pathways for object-oriented action and object recognition: functional anatomy with PET. *Cereb Cortex* 7:77–85.
- Friederici AD (1997): Autonomy of syntactic processing and the role of Broca's area. *Behav Brain Sci* 19:634–635.
- Galaburda AM, Pandya DN (1982): Role of architectonics and connections in the study of primate brain evolution. In: Armstrong E, Falk D, editors. *Primate brain evolution: methods and concepts*. New York: Plenum Press. p 203–216.
- Gallese V, Fadiga L, Fogassi L, Rizzolatti G (1996): Action recognition in the premotor cortex. *Brain* 119:593–609.
- Geyer S, Schormann T, Zilles K (1998): Receptor autoradiographic mapping of the mesial motor and premotor cortex of the rhesus monkey. *J Comp Neurol* 397:231–250.
- Goebel R, Khorrarn-Sefat D, Muckli L, Hacker H, Singer W (1998): The constructive nature of vision: direct evidence from functional magnetic resonance imaging studies of apparent motion and motion imagery. *Eur J Neurosci* 10:1563–1573.
- Grafton ST, Mazziotta JC, Woods RP, Phelps ME (1992): Human functional anatomy of visually guided finger movements. *Brain* 115:565–587.
- Grafton ST, Fagg AH, Woods RP, Arbib MA (1996a): Functional anatomy of pointing and grasping in humans. *Cereb Cortex* 6:226–237.
- Grafton ST, Arbib MA, Fadiga L, Rizzolatti G (1996b): Localization of grasp representations in humans by positron emission tomography. *Exp Brain Res* 112:103–111.
- Halsband U, Freund H-J (1990): Premotor cortex and conditional motor learning in man. *Brain* 113:207–222.
- Hazeltine E, Grafton ST, Ivry D (1997): Attention and stimulus characteristics determine the locus of motor-sequence encoding. A PET study. *Brain* 120:123–140.
- Heide W, Binkofski F, Posse S, Seitz RJ, Kömpf D, Freund H-J (1999): Cortical control of sequential memory-guided saccades. In: Becker W, Deubel H, Mergner T, editors. *Current oculomotor research: physiological and psychological aspects*. New York: Plenum Press, pp 223–233.
- Hepp-Reymond MC, Husler EJ, Maier MA, Qi HX (1994): Force-related neuronal activity in two regions of the primate ventral premotor cortex. *Can J Physiol Pharmacol* 72:571–579.
- Jahanshahi M, Jenkins H, Brown RG, Marsden CD, Passingham RE, Brooks DJ (1995): Self-initiated versus externally triggered movements. I. An investigation using measurement of regional cerebral blood flow with PET and movement-related potentials in normal and Parkinson's disease subjects. *Brain* 118:913–933.
- Jeannerod M (1994): The representing brain: neural correlates of motor imagery and intention. *Behav Brain Sci* 17:187–245.
- Jeannerod M, Arbib MA, Rizzolatti G, Sakata H (1995): Grasping objects: the cortical mechanisms of visuomotor transformation. *Trends Neurosci* 18:314–320.
- Kim KH, Relkin NR, Lee KM, Hirsch J (1997): Distinct cortical areas associated with native and second languages. *Nature* 388:171–174.
- Kononova EP (1949): The frontal lobe. The cytoarchitecture of the human cortex cerebri (Russian). Sarkisov SA, Filimonov IN, Preobrashenskaya NS, editors. Moscow: Medgiz, p 309–343.
- Kurata K, Tanji J (1986): Premotor cortex neurons in macaques: activity before distal and proximal forelimb movements. *Neuroscience* 6:403–411.
- Lacquaniti F, Perani D, Guigon E, Bettinardi V, Carrozzo M, Grassi F, Rossetti Y, Fazio F (1997): Visuomotor transformations for reaching to memorized targets: a PET study. *Neuroimage* 5:129–146.
- Lieberman AM (1996): *Speech: a special code*. Cambridge, MA: MIT Press.
- Luna B, Thulborn KR, Strojwas MH, McCurtain BJ, Berman RA, Genovese CR, Sweeney JA (1998): Dorsal regions subserving visually guided saccades in humans: an fMRI study. *Cereb Cortex* 8:40–47.
- Luppino G, Matelli M, Camarda RM, Gallese V, Rizzolatti G (1991): Multiple representations of body movements in mesial area 6 and the adjacent cingulate cortex: an intracortical microstimulation study in the macaque monkey. *J Comp Neurol* 311:463–482.
- MacKinnon CD, Kapur S, Hussey D, Verrier MC, Houle S, Tatton WG (1996): Contributions of the mesial frontal cortex to the premovement potentials associated with intermittent hand movements in humans. *Hum Brain Mapp* 4:1–22.
- Matelli M, Luppino G, Rizzolatti G (1991): Architecture of superior and mesial area 6 and the adjacent cingulate cortex in the macaque monkey. *J Comp Neurol* 311:445–462.
- Merker B (1983): Silver staining of cell bodies by means of physical development. *J Neurosci Methods* 9:235–241.
- Merzenich MM, Jenkins WM, Johnston P, Schreiner C, Miller SL, Tallal P (1996): Temporal processing deficits of language-learning impaired children ameliorated by training. *Science* 271:77–81.
- Mesulam M-M (1990): Large-scale neurocognitive networks and distributed processing for attention, language, and memory. *Ann Neurol* 2:597–613.
- Murata A, Fadiga L, Fogassi L, Gallese V, Raos V, Rizzolatti G (1997): Object representation in the ventral premotor cortex (area F5) of the monkey. *J Neurophysiol* 78:2226–2230.
- Ojemann GA (1993): Functional mapping of cortical language areas in adults. Intraoperative approaches. *Adv Neurol* 63:155–163.
- Oldfield RC (1971): The assessment and analysis of handedness: the Edinburgh Inventory. *Neuropsychologia* 9:97–104.

- Pardo JV, Fox PT, Janer KW, Raichle ME (1990): The anterior cingulate cortex mediates processing selection in the Stroop attentional conflict paradigm. *Proc Natl Acad Sci U S A* 87:256–259.
- Parsons LM, Fox PT, Downs JH, Glaas T, Hirsch TB, Martin CC, Jerabek PA, Lancaster JL (1995): Use of implicit motor imagery for visual shape discrimination as revealed by PET. *Nature* 375:54–58.
- Parsons LM, Fox PT (1997): Sensory and cognitive functions. *Rev Neurobiol* 41:255–271.
- Peters M, Laeng B, Latham K, Jackson M, Zaiyouna R, Richardson C (1995): A redrawn Vandenberg and Kuse mental rotations test: different versions and factors that affect performance. *Brain Cognition* 28:39–58.
- Petersen SE, Fox PT, Snyder AZ, Raichle ME (1988): Positron emission tomographic studies of the cortical anatomy of single-word processing. *Nature* 331:585–589.
- Petrides M, Pandya DN (1994): Comparative architectonic analysis of the human and macaque frontal cortex. In: Grafman J and Boller F, editors. *Handbook of neuropsychology*. Amsterdam: Elsevier.
- Porro CA, Francescato MP, Cettolo V, Diamond ME, Baraldi P, Zuiani C, Bazzocchi M, di Prampero PE (1996): Primary motor and sensory cortex activation during motor performance and motor imagery: a functional magnetic resonance imaging study. *J Neurosci* 16:7688–7698.
- Preuss TM, Stepniewska I, Kaas JH (1996): Movement representation in the dorsal and ventral premotor areas of owl monkeys: a microstimulation study. *J Comp Neurol* 371:649–675.
- Pugh KR, Offywitz BA, Shaywitz SE, Fulbright RK, Byrd D, Skudlarski P, Shankweiler DP, Katz L, Constable RT, Fletcher J, Lacadie C, Marchione K, Gore JC (1996): Auditory selective attention: an fMRI investigation. *Neuroimage* 4:159–173.
- Rademacher J, Caviness VS, Steinmetz H, Galaburda AM (1993): Topographical variation of the human primary cortices: implications for neuroimaging and brain mapping studies. *Cereb Cortex* 3:313–329.
- Rauch SL, Savage CR, Brown HD, Curran T, Alpert NM, Kendrick A, Fischman AJ, Kosslyn SM (1995): A PET investigation of implicit and explicit sequence learning. *Hum Brain Mapp* 3:271–286.
- Rizzolatti G, Scandolaria C, Matelli M, Gentilucci M (1981): Afferent properties of periarculate neurons in macaque monkeys. I. Somatosensory responses. *Behav Brain Res* 2:125–146.
- Rizzolatti G, Camarda R, Fogassi L, Gentilucci M (1988): Functional organization of inferior area 6 in the macaque monkey. II. Area F5 and the control of distal movements. *Exp Brain Res* 71:491–507.
- Rizzolatti G, Fadiga L, Fogassi L, Gallese V (1997): The space around us. *Science* 277:190–191.
- Roland PE, Zilles K (1994): Brain atlases - a new research tool. *Trends Neurosci* 17:458–467.
- Roth M, Decety J, Raybaudi M, Massarelli R, Delon-Martin C, Seguebarth C, Morand S, Gemignani A, Décorps M, Jeannerod M (1996): Possible involvement of primary motor cortex in mentally simulated movement: a functional magnetic resonance imaging study. *Neuroreport* 7:1280–1284.
- Sakai K, Hikosaka O, Miyauchi S, Takino R, Sasaki Y, Pütz B (1998): Transition of brain activation from frontal to parietal areas in visuomotor sequence learning. *J Neurosci* 18:1827–1840.
- Sakata H, Taira M, Murata A (1992): Hand-movements related neurons of the posterior parietal cortex of the monkey: their role in visual guidance of hand movements. In: Caminiti R, Johnson PB, Burnod Y, editors. *Control of arm movements in space: neurophysiological and computational approaches*. Berlin: Springer.
- Schäffler L, Lüders HO, Dinner DS, Lesser RP, Chelune GJ (1993): Comprehension deficits elicited by electrical stimulation of Broca's area. *Brain* 116:695–715.
- Schleicher A, Zilles K (1990): A quantitative approach to cytoarchitectonics: analysis of structural inhomogeneities in nervous tissue using an image analyser. *J Microscopy* 157:367–381.
- Schormann T, Henn S, Zilles K (1996): A new approach to fast elastic alignment with applications to human brains. *Lect Notes Comput Sci* 1131:337–342.
- Seitz RJ, Roland PE (1992): Learning of sequential finger movements in man: a combined kinematic and positron emission tomography study. *Eur J Neurosci* 4:154–165.
- Seitz RJ, Canavan AGM, Yagüez L, Herzog H, Tellmann L, Knorr U, Huang Y, Hömberg V (1997): Representation of graphomotor trajectories in human parietal cortex: evidence for controlled processing and skilled performance. *Eur J Neurosci* 9:378–389.
- Shima K, Aya K, Mushiake H, Inase M, Aizawa H, Tanji J (1991): Two movement-related foci in the primate cingulate cortex observed in signal-triggered and self-paced forelimb movements. *J Neurophysiol* 65:188–202.
- Stephan KM, Fink GR, Passingham RE, Silberzweig D, Ceballos-Baumann AO, Frith CD, Frackowiak RSJ (1995): Functional anatomy of the mental representation of upper extremity movements in healthy subjects. *J Neurophysiol* 73:373–386.
- Stromswold K, Caplan D, Alpert N, Rauch S (1996): Localization of syntactic comprehension by positron emission tomography. *Brain Lang* 52:452–473.
- Swaab T, Brown C, Hagoort P (1995): Delayed integration of lexical ambiguities in Broca's aphasics: evidence from event-related potentials. *Brain Lang* 51:159–161.
- Tailarach J, Tournoux P (1988): Co-planar stereotaxic atlas of the human brain. 3-dimensional proportional system: an approach to cerebral imaging. Stuttgart and New York: Thieme Verlag.
- Tamaiulo F, MacDonald JD, Caramanos Z, Posner G, Chiavaras M, Evans AC, Petrides M (1999): Morphology, morphometry and probability mapping of the pars opercularis of the inferior frontal gyrus: an in vivo MRI analysis. *Eur J Neurosci* 11:3033–3046.
- Tanji J (1994): The supplementary motor area in the cerebral cortex. *Neurosci Res* 19:251–268.
- Tootell RBH, Reppas JB, Dale AM, Look RB, Sereno MI, Malach R, Brady TJ, Rosen BR, Belliveau JWJ (1995): Functional analysis of human MT and related visual cortical areas using magnetic resonance imaging. *J Neurosci* 15:3215–3230.
- Vallar G, Lobel E, Galati G, Berthoz a, Pizzamiglio L, LeBihan D. A fronto-parietal system for computing the egocentric spatial frame of reference in humans. *Exp Brain Res* 124:281–286.
- von Bonin G, Bailey P (1947): *The neocortex of Macaca Mulatta*. Urbana: University of Illinois Press.
- Watson JDG, Myers R, Frackowiak RSJ, Hajnal JV, Woods RP, Mazziotta JC, Shipp S, Zeki S (1993): Area V5 of the human brain: evidence from a combined study using positron emission tomography and magnetic resonance imaging. *Cereb Cortex* 3:79–94.
- Wise R, Chollet F, Hadar U, Friston K, Hoffner E, Frackowiak RSJ (1991a): Distribution of cortical neural networks involved in word comprehension and word retrieval. *Brain* 114:1803–1817.
- Wise SP (1991): What are the specific functions of the different motor areas? In: Humphrey DR, Freund H-J, editors. *Motor control: concepts and issues*. New York: Wiley & Sons, p 463–485.
- Zatorre RJ, Evans AC, Meyer E, Gjedde A (1992): Lateralization of phonetic and pitch discrimination in speech processing. *Science* 256:846–849.
- Zatorre RJ, Meyer E, Gjedde A, Evans AC (1996): PET studies of phonetic processing of speech: review, replication, and reanalysis. *Cereb Cortex* 6:21–30.