

ANATOMICAL VARIATIONS OF RECURRENT LARYNGEAL NERVE DURING THYROID SURGERY: HOW TO IDENTIFY AND HANDLE THE VARIATIONS WITH INTRAOPERATIVE NEUROMONITORING

Feng-Yu Chiang,^{1,2} I-Cheng Lu,³ Hui-Chun Chen,⁴ Hsiu-Ya Chen,³ Cheng-Jing Tsai,³
Pi-Jung Hsiao,^{2,5} Ka-Wo Lee,^{1,2} and Che-Wei Wu^{6,7}

Departments of ¹Otolaryngology, ³Anesthesiology and ⁴Nursing, and ⁵Endocrinology and Metabolism Division, Department of Internal Medicine, Kaohsiung Medical University Hospital, ⁶Department of Otolaryngology, Kaohsiung Municipal Hsiao-Kang Hospital, and ²Faculty of Medicine, ⁷Institute of Clinical Medicine, College of Medicine, Kaohsiung Medical University, Kaohsiung, Taiwan.

Recurrent laryngeal nerve (RLN) palsy is the most common and serious complication after thyroid surgery. Visual identification of the RLN during thyroid surgery has been shown to be associated with lower rates of palsy, and although it has been recommended as the gold standard for RLN treatment, it does not guarantee success against postoperative vocal cord paralysis. Anatomical variations of the RLN, such as extra-laryngeal branches, distorted RLN, intertwining between branches of the RLN and inferior thyroid artery, and non-recurrent laryngeal nerve, can be a potential cause of nerve injury due to visual misidentification. Therefore, intraoperative verification of functional and anatomical RLN integrity is a prerequisite for a safe thyroid operation. In this article, we review the literature and demonstrate how to identify and handle the anatomical variations of the RLN with the application of intraoperative neuromonitoring in the form of high-resolution photography, which can be informative for thyroid surgeons. Anatomical variations of the RLN cannot be predicted preoperatively and might be associated with higher rates of RLN injury. The RLN injury caused by visual misidentification can be rare if the nerve is definitely identified early with intraoperative neuromonitoring.

Key Words: anatomical variations, intraoperative neuromonitoring, laryngeal electromyography, recurrent laryngeal nerve, thyroid surgery
(*Kaohsiung J Med Sci* 2010;26:575–83)

Part of this work was presented at the World Congress on Thyroid Cancer in Toronto, Canada, 2009; and 4th World Congress of International Federation of Head and Neck Oncologic Societies in Seoul, Korea, 2010.



ELSEVIER

Received: Jul 19, 2010 Accepted: Jul 28, 2010
Address correspondence and reprint requests to:
Dr Che-Wei Wu, Department of Otolaryngology,
Kaohsiung Medical University Hospital, 100
Tzyou 1st Road, Kaohsiung 807, Taiwan.
E-mail: kmuent@yahoo.com.tw

Visual identification of the recurrent laryngeal nerve (RLN) during thyroid surgery has been shown to be associated with lower rates of RLN palsy [1–10], but it does not guarantee success against an outcome of postoperative vocal cord paralysis. RLN palsy has still been reported with permanent palsy rates of 1–2% [11–14] and temporary palsy rates of up to 5–6% [1,3,15]. Furthermore, most RLN injuries are not recognized

intraoperatively [1,16,17], although the possible causes of RLN injury can result from transection, clamping, stretching, electrothermal injury, ligature entrapment or ischemia. Several studies have reported that anatomical variations of the RLN [7,18–22], such as extralaryngeal branches, distorted RLN, intertwining between branches of the RLN and inferior thyroid artery (ITA), and non-recurrent laryngeal nerve (non-RLN), play an important role in the occurrence of nerve injury that can be caused by visual misidentification. Unrecognized transection of the RLN or its motor branch can be a cause of unexpected permanent palsy of these nerves. Therefore, intraoperative verification of functional and anatomical RLN integrity is a prerequisite for a safe thyroid operation, and it has also played a crucial role in the development of modern thyroid surgery. In our clinical practice, during thyroid surgery since April 2006, all exposed RLNs have been electromyographically documented with intraoperative neuromonitoring (IONM) to show functional nerve integrity, and all have been photographically documented with a high-resolution camera to show anatomical nerve integrity during the operation [15,23–25].

In this article, we review the literature and demonstrate how to identify and handle the anatomical variations in the RLN using IONM in the form of high-resolution photography, which could be informative for thyroid surgeons.

ANATOMICAL VARIATIONS IN THE RLN

Extralaryngeal branches

Extralaryngeal branches of the RLN are a common anatomical variant [12,18–20]. Beneragama and Serpell reported 36% bifurcation or trifurcation in 213 nerves [18]. Katz reported that 58% of 1,177 RLNs were found to be branched before entering the larynx [19]. In the experience of Randolph [26], 50–60% of patients have some small branches of the RLN to the trachea, esophagus, or inferior constrictor muscle, but only 30% have true RLN extralaryngeal branches (anterior and posterior branches) that enter the larynx, and anterior and posterior branches, when present, usually exist at the level of the ligament of Berry. Casella and his colleagues reported that branched RLN represents a risk factor for transient and permanent nerve palsy after surgery [20]. Awareness of this anatomical variation and its routine investigation are essential during

thyroid surgery, to limit its impact on postoperative RLN injury rate.

To identify the extralaryngeal branches and avoid visual misidentification, we recommend that the RLN should be localized and identified definitely with IONM at the level of the ITA (Figure 1A). Then, the branches to the inferior constrictor muscle, esophagus (Figure 1B), and the anterior and posterior branches (Figure 1C) can be easily identified and preserved as the RLN is dissected to the entry of the larynx.

In our experience, the electromyography (EMG) signal and twitch of the larynx can be induced only on the anterior branch as the branches are tested with IONM. In the study of Maranillo and his colleagues [27], no abductor or adductor division of the RLN was found. Serpell et al also reported that the motor fibers of the RLN are located in the anterior extralaryngeal branch [28]. This information suggests that most motor fibers to adductors and abductors of the laryngeal muscles arise from the anterior branch. In some circumstances, the anterior branch of the RLN can be stretched forward by Berry's ligament. It often swerves anteriorly within Berry's ligament and can appear like a small artery (Figure 2). Besides, the diameter of the posterior branch of the RLN can sometimes be larger than that of the anterior branch (Figure 3), and the bifurcation can occur at the level of the ITA (Figures 4A and 4B). In this situation, partial exposure of the nerve at the region of Berry's ligament alone can place the RLN at a high risk of injury. However, these variations and pitfalls can be easily recognized if the RLN is identified at the level of the ITA and confirmed with IONM.

In our clinical practice, we use the NIM-Response 2.0 monitoring system for IONM (Medtronic Xomed, Jacksonville, FL, USA) [15,23–25]. A Pass monopolar stimulation probe (Medtronic Xomed) was used for nerve stimulation during the thyroidectomy procedure. We always test the RLN with a stimulation level of 1 mA. In case two structures run close together (anterior and posterior branches of the RLN, or a small artery and RLN), a false EMG signal can be induced by a shunt stimulus, we lower the stimulation level to 0.5 mA. In our human data that are in preparation for publication, we have checked the threshold of the RLN after resection of the thyroid lobe. The RLN was tested with 1.0 mA down to 0.1 mA, and we found that there was no significant difference between the magnitude of EMG amplitude that was elicited with

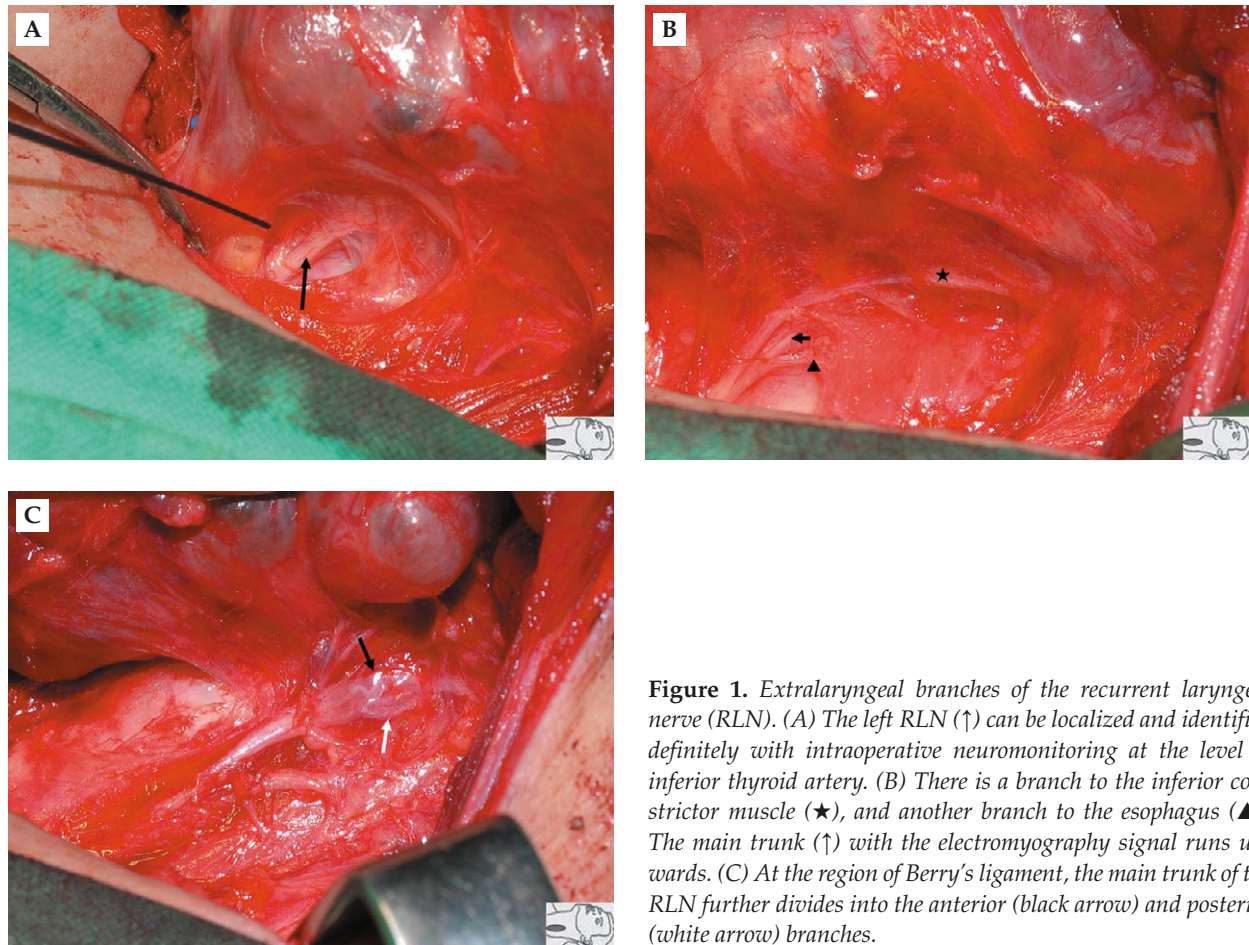


Figure 1. Extralaryngeal branches of the recurrent laryngeal nerve (RLN). (A) The left RLN (↑) can be localized and identified definitely with intraoperative neuromonitoring at the level of inferior thyroid artery. (B) There is a branch to the inferior constrictor muscle (★), and another branch to the esophagus (▲). The main trunk (↑) with the electromyography signal runs upwards. (C) At the region of Berry's ligament, the main trunk of the RLN further divides into the anterior (black arrow) and posterior (white arrow) branches.

1.0mA, 0.8mA or 0.5mA on the bare RLN under bloodless conditions. In this context, it seems to be reasonable and adequate to lower the stimulation to 0.5mA if one wants to differentiate a motor branch from a sensory branch, or a small artery from the RLN.

Distorted RLN

RLN position can be significantly abnormal in patients with large goiter with substernal extension or recurrent large goiter. Randolph stated that the RLN can be displaced in any direction and might even come to lie ventral to the inferior pole [26]. This is a very disorienting position to come upon and places the nerve at extreme risk, even in experienced hands. During dissection of large goiter, the RLN can be distorted due to medical traction (Figure 5). Sometimes, the RLN can be found adherent to the capsule of a large recurrent goiter at the lateral position (Figure 6). In these situations, the distorted nerve can be mistaken for a blood vessel and be transected inadvertently. With the application of IONM, these variations and pitfalls

can be easily recognized, and the distorted RLN can be easily identified and preserved. We therefore recommend not clamping or transecting any structure during lateral dissection of the thyroid before definite identification of the RLN with IONM.

Intertwining between branches of the RLN and ITA

The relationship between the RLN and ITA is highly variable [29]. A particularly high-risk situation occurs when the ITA is also divided into many ramifications close to the RLN, and the branches of both structures intertwine (Figures 7–9). Some nerve injuries can be caused by clamping or electro-cauterization in an attempt to stop bleeding. Therefore, a bloodless situation should always be maintained by careful hemostasis. Sometimes, the RLN can run parallel to a branch of the ITA, and visual misidentification can occur if the RLN is partially exposed. Therefore, we recommend that the RLN should be identified and followed through Berry's ligament until the nerve enters the

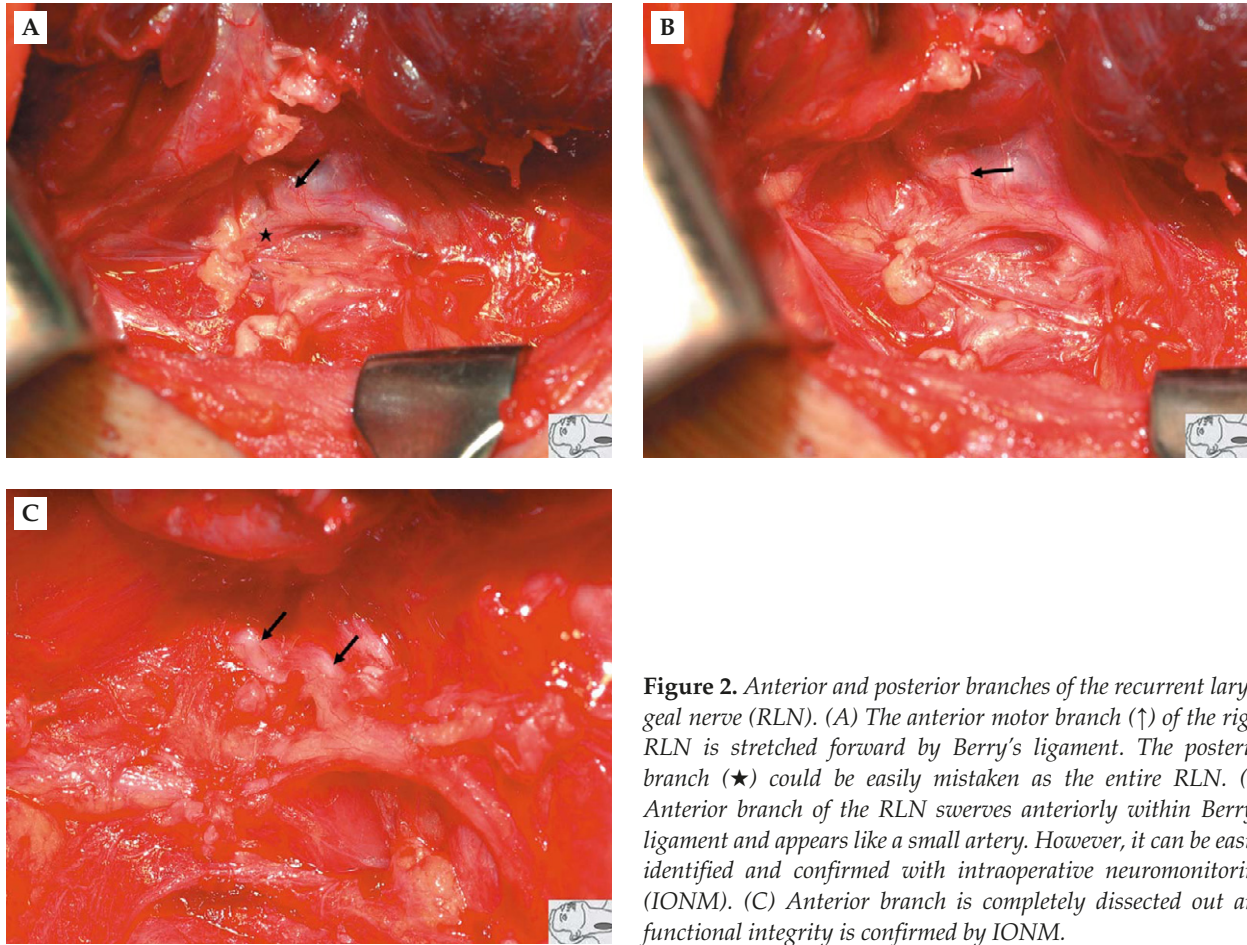


Figure 2. Anterior and posterior branches of the recurrent laryngeal nerve (RLN). (A) The anterior motor branch (↑) of the right RLN is stretched forward by Berry's ligament. The posterior branch (★) could be easily mistaken as the entire RLN. (B) Anterior branch of the RLN swerves anteriorly within Berry's ligament and appears like a small artery. However, it can be easily identified and confirmed with intraoperative neuromonitoring (IONM). (C) Anterior branch is completely dissected out and functional integrity is confirmed by IONM.

larynx. Furthermore, we also recommend the use of IONM, because we have found with this technique that the intertwined RLN and ITA can be easily distinguished intraoperatively (Figures 8 and 9).

Non-RLN

The non-RLN is a rare variant with an incidence of 0.3–1.6%, and most are observed on the right side. It is highly predisposed to injury during thyroidectomy due to misidentification. Toniato and his colleagues reported 31 cases (0.51%) of non-RLN in 6,000 thyroidectomies, and all were observed on the right side [21]. Nerve injury was observed in four patients (12.9%): in three cases in which the nerve ran along the vessels of the superior thyroid peduncle, and in one case in which the nerve was close to the branches of the ITA. Non-RLN can be divided into type I and II anomalies. A type I non-RLN (Figure 10A) can be easily mistaken as a branch of the superior thyroid artery, and a type II non-RLN (Figure 10B) for a branch of the ITA. In our unpublished data, we have experienced one type I and three type II non-RLNs in 603 thyroidectomies (0.66%). In

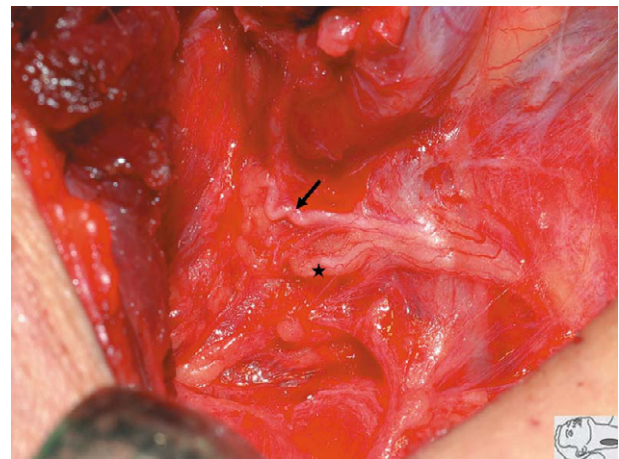


Figure 3. Posterior branch (★) of right recurrent laryngeal nerve looks larger in diameter than the anterior branch (↑). Neither electromyographic signal nor laryngeal twitch is detectable when the posterior branch is stimulated.

these cases, all the non-RLNs were observed on the right side and were detected at the early stage of operation due to a negative response to distal vagal stimulation but a positive response to proximal vagal stimulation.

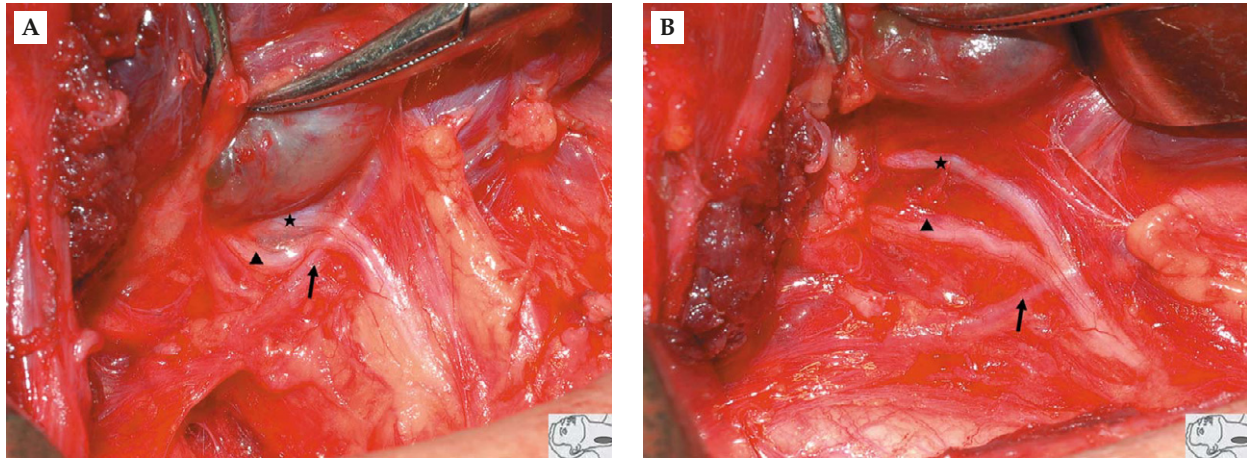


Figure 4. Bifurcation of anterior (★) and posterior (▲) branches of the recurrent laryngeal nerve can occur at the level of the inferior thyroid artery (↑). (A) Before dissection. (B) After dissection, the functional integrity of the anterior motor branch is confirmed by intraoperative neuromonitoring. Neither electromyographic signal nor laryngeal twitch can be detected when the posterior branch is stimulated.

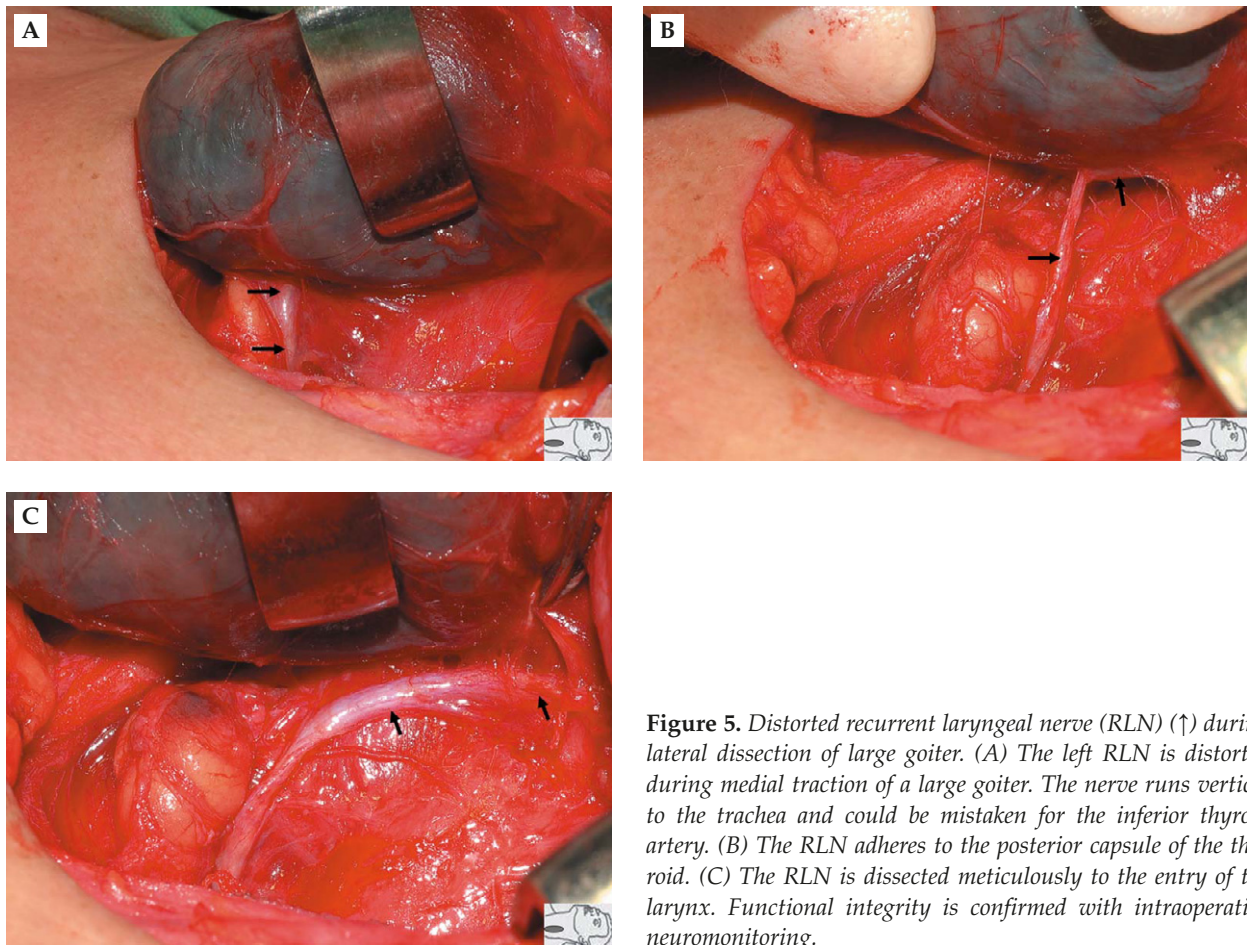


Figure 5. Distorted recurrent laryngeal nerve (RLN) (↑) during lateral dissection of large goiter. (A) The left RLN is distorted during medial traction of a large goiter. The nerve runs vertical to the trachea and could be mistaken for the inferior thyroid artery. (B) The RLN adheres to the posterior capsule of the thyroid. (C) The RLN is dissected meticulously to the entry of the larynx. Functional integrity is confirmed with intraoperative neuromonitoring.

**METHOD OF APPROACH TO THE RLN:
OUR EXPERIENCE**

The method of approach to the RLN plays an important role in prevention of injury. In the earlier period

of our use of IONM (from April 2006 to August 2007, 113 patients with 173 nerves at risk), the RLN was always identified where it coursed through Berry’s ligament, or was close to it with visualization and IONM. With this approach, the RLN is identified at a

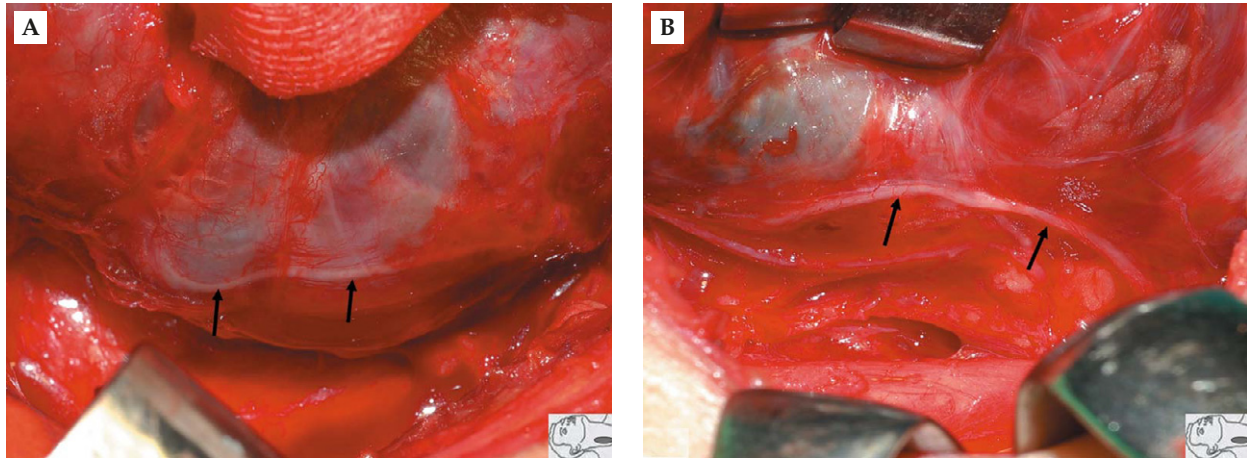


Figure 6. Distorted recurrent laryngeal nerve (RLN) (↑) due to recurrent goiter. (A) The right RLN is adherent to the capsule of a large recurrent goiter at the lateral position. The nerve can be localized and identified with intraoperative neuromonitoring (IONM). (B) The RLN is dissected completely from the thyroid gland, and the functional integrity can be confirmed with IONM.

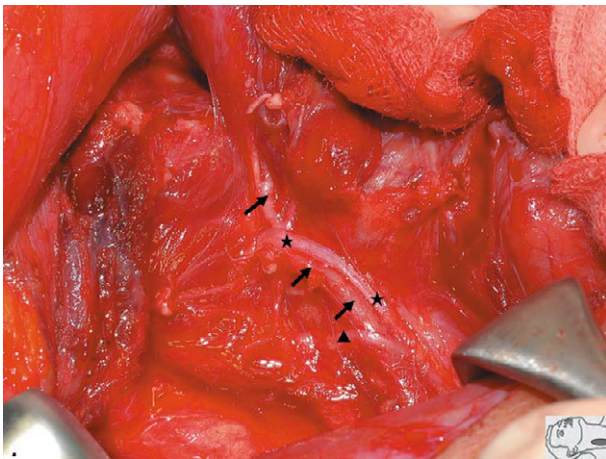


Figure 7. Intertwining between the branches of the recurrently laryngeal nerve (RLN) and inferior thyroid artery (ITA). The ITA (↑) runs between the anterior (★) and posterior branches (▲) of the RLN.

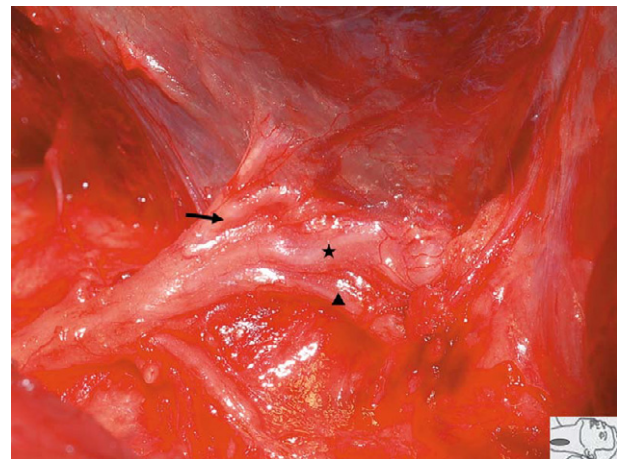


Figure 8. Complex relationship between the branches of the recurrent laryngeal nerve (RLN) and inferior thyroid artery (ITA). With the application of neuromonitoring, the anterior (★) and posterior (▲) branches of the RLN, and the ITA (↑) can be easily distinguished.

higher position, which allows for a more limited segment of RLN dissection. However, under partial exposure of the RLN, we have experienced higher rates of nerve injury: one transection, two clamping and eight stretch injuries. The permanent and temporary palsy rates were 0.6% and 5.8% [15,25]. In the later period (from September 2007 to May 2010, 277 patients with 430 nerves at risk), we changed the method of RLN approach. The RLN was localized and identified with IONM at the level of the ITA, and then dissected completely to the entry of the larynx. Gentle traction of the thyroid is used all the time, and we never clamp or transect any structure during lateral dissection of the thyroid before definite identification

of the RLN with IONM. We have found that all extralaryngeal branches of the RLN and most inferior parathyroid glands with its feeding vessels can be well visualized and preserved with this method of RLN approach. No inadvertent transection or clamping injury occurs, and the temporary palsy rates can be further reduced to <1% and the permanent palsy rates to zero.

CONCLUSIONS AND FUTURE PERSPECTIVE

When performing a total lobectomy, the RLN is at greatest risk at the region of Berry's ligament [2,7,15,30].

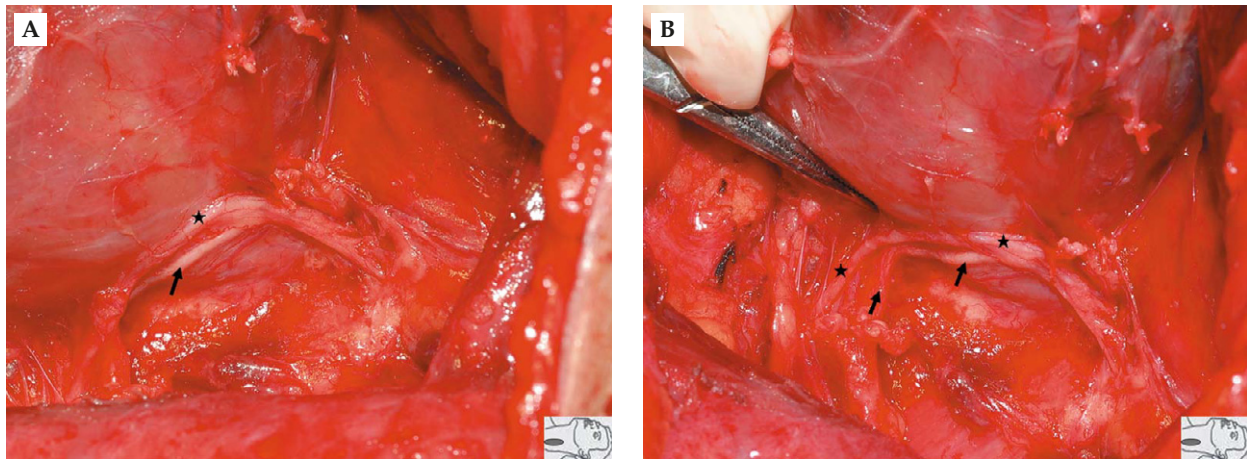


Figure 9. (A) The left recurrent laryngeal nerve (RLN) (★) runs parallel to the branch of the inferior thyroid artery (ITA) (↑). (B) When tracing back to their origin, the RLN and the branch of the ITA can be well differentiated. The superior structure is the RLN and confirmed by intraoperative neuromonitoring. The inferior structure is a branch of the ITA.

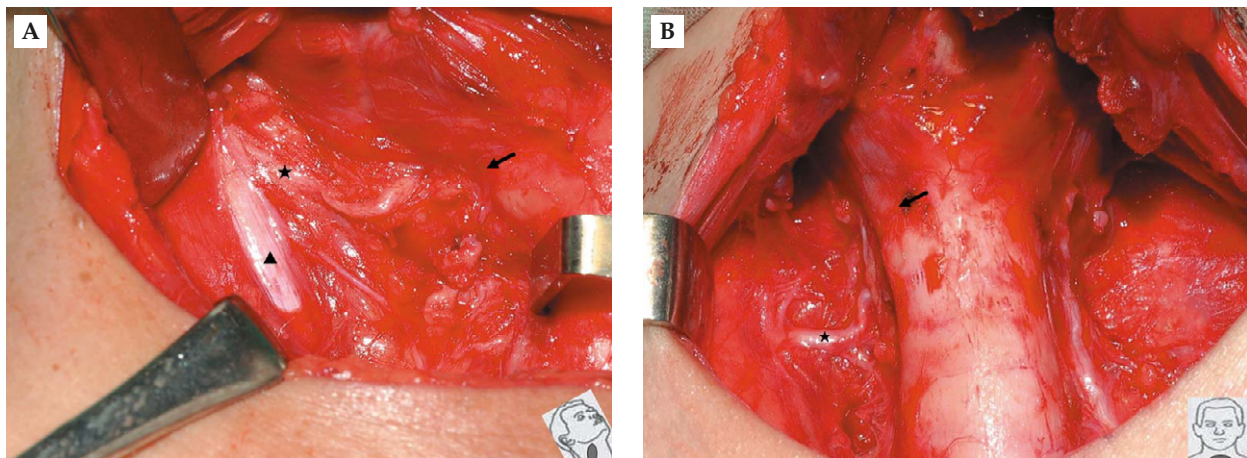


Figure 10. Non-recurrent laryngeal nerve (non-RLN). (A) A type I anomaly in which the right non-RLN (★) stems from the vagus nerve (▲) above the laryngotracheal junction (↑) and descends into the larynx. It mimics a branch of the vessels of the superior thyroid pedicle. (B) A type II anatomical variant in which the right non-RLN (★) arises from the vagus nerve below the laryngotracheal junction (↑) and runs parallel to the path of the inferior thyroid artery.

The RLN can be injured because of visual misidentification under partial exposure of the nerve, especially when the anatomy of the RLN is challenging. We recommend that the RLN should be localized and identified definitely with IONM at the level of the ITA, and then meticulously dissected to the entry of the larynx. This is a more reliable and safer way to preserve all branches of the RLN. For safe thyroid operations and the development of modern thyroid surgery, intraoperative verification and documentation of functional and anatomical RLN integrity are suggested as standards of care. All exposed RLNs should be electromyographically documented with

IONM to show functional nerve integrity, and all nerves should be photographically documented with a high-resolution camera to show anatomical nerve integrity.

ACKNOWLEDGMENTS

This study was supported by grants from Kaohsiung Medical University Research Foundation (KMU-M099001) and the National Science Council (NSC 99-2314-B-037-015-MY2). We thank the study participants for their contribution to this study.

REFERENCES

1. Chiang FY, Lee KW, Huang YF, et al. Risk of vocal palsy after thyroidectomy with identification of the recurrent laryngeal nerve. *Kaohsiung J Med Sci* 2004;20:431–6.
2. Lore JM, Jr., Kim DJ, Elias S. Preservation of the laryngeal nerves during total thyroid lobectomy. *Ann Otol Rhinol Laryngol* 1977;86:777–88.
3. Harness JK, Fung L, Thompson NW, et al. Total thyroidectomy: complications and technique. *World J Surg* 1986;10:781–6.
4. Jatzko GR, Lisborg PH, Muller MG, et al. Recurrent nerve palsy after thyroid operations—principal nerve identification and a literature review. *Surgery* 1994;115:139–44.
5. Hermann M, Alk G, Roka R, et al. Laryngeal recurrent nerve injury in surgery for benign thyroid diseases: effect of nerve dissection and impact of individual surgeon in more than 27,000 nerves at risk. *Ann Surg* 2002;235:261–8.
6. Karlan MS, Catz B, Dunkelman D, et al. A safe technique for thyroidectomy with complete nerve dissection and parathyroid preservation. *Head Neck Surg* 1984;6:1014–9.
7. Snyder SK, Lairmore TC, Hendricks JC, et al. Elucidating mechanisms of recurrent laryngeal nerve injury during thyroidectomy and parathyroidectomy. *J Am Coll Surg* 2008;206:123–30.
8. Bellantone R, Lombardi CP, Bossola M, et al. Total thyroidectomy for management of benign thyroid disease: review of 526 cases. *World J Surg* 2002;26:1468–71.
9. Reeve T, Thompson NW. Complications of thyroid surgery: how to avoid them, how to manage them, and observations on their possible effect on the whole patient. *World J Surg* 2000;24:971–5.
10. Bliss RD, Gauger PG, Delbridge LW. Surgeon's approach to the thyroid gland: surgical anatomy and the importance of technique. *World J Surg* 2000;24:891–7.
11. Beldi G, Kinsbergen T, Schlumpf R. Evaluation of intraoperative recurrent nerve monitoring in thyroid surgery. *World J Surg* 2004;28:589–91.
12. Snyder SK, Hendricks JC. Intraoperative neurophysiology testing of the recurrent laryngeal nerve: plaudits and pitfalls. *Surgery* 2005;138:1183–92.
13. Yarbrough DE, Thompson GB, Kasperbauer JL, et al. Intraoperative electromyographic monitoring of the recurrent laryngeal nerve in reoperative thyroid and parathyroid surgery. *Surgery* 2004;136:1107–15.
14. Chiang FY, Lin JC, Wu CW, et al. Morbidity after total thyroidectomy for benign thyroid disease: comparison of Graves' disease and non-Graves' disease. *Kaohsiung J Med Sci* 2006;22:554–9.
15. Chiang FY, Lu IC, Kuo WR, et al. The mechanism of recurrent laryngeal nerve injury during thyroid surgery—the application of intraoperative neuromonitoring. *Surgery* 2008;143:743–9.
16. Patow CA, Norton JA, Brennan MF. Vocal cord paralysis and reoperative parathyroidectomy. A prospective study. *Ann Surg* 1986;203:282–5.
17. Chan WF, Lang BH, Lo CY. The role of intraoperative neuromonitoring of recurrent laryngeal nerve during thyroidectomy: a comparative study on 1000 nerves at risk. *Surgery* 2006;140:866–73.
18. Beneragama T, Serpell JW. Extralaryngeal bifurcation of the recurrent laryngeal nerve: a common variation. *ANZ J Surg* 2006;76:928–31.
19. Katz AD. Extralaryngeal division of the recurrent laryngeal nerve. Report on 400 patients and the 721 nerves measured. *Am J Surg* 1986;152:407–10.
20. Casella C, Pata G, Nascimbeni R, et al. Does extralaryngeal branching have an impact on the rate of postoperative transient or permanent recurrent laryngeal nerve palsy? *World J Surg* 2009;33:261–5.
21. Toniato A, Mazzarotto R, Piotta A, et al. Identification of the nonrecurrent laryngeal nerve during thyroid surgery: 20-year experience. *World J Surg* 2004;28:659–61.
22. Hermann M, Hellebart C, Freissmuth M. Neuromonitoring in thyroid surgery: prospective evaluation of intraoperative electrophysiological responses for the prediction of recurrent laryngeal nerve injury. *Ann Surg* 2004;240:9–17.
23. Lu IC, Chu KS, Tsai CJ, et al. Optimal depth of NIM EMG endotracheal tube for intraoperative neuromonitoring of the recurrent laryngeal nerve during thyroidectomy. *World J Surg* 2008;32:1935–9.
24. Chu KS, Wu SH, Lu IC, et al. Feasibility of intraoperative neuromonitoring during thyroid surgery after administration of nondepolarizing neuromuscular blocking agents. *World J Surg* 2009;33:1408–13.
25. Chiang FY, Lee KW, Chen HC, et al. Standardization of intraoperative neuromonitoring of recurrent laryngeal nerve in thyroid operation. *World J Surg* 2010;34:223–9.
26. Randolph GW. Surgical anatomy of the recurrent laryngeal nerve. In: Randolph GW, 1st edition. *Surgery of the Thyroid and Parathyroid Glands*, edition. Philadelphia: Saunders, 2003:300–42.
27. Maranillo E, Leon X, Orus C, et al. Variability in nerve patterns of the adductor muscle group supplied by the recurrent laryngeal nerve. *Laryngoscope* 2005;115:358–62.
28. Serpell JW, Yeung MJ, Grodski S. The motor fibers of the recurrent laryngeal nerve are located in the anterior extralaryngeal branch. *Ann Surg* 2009;249:648–52.
29. Yalcin B. Anatomic configurations of the recurrent laryngeal nerve and inferior thyroid artery. *Surgery* 2006;139:181–7.
30. Thompson NW, Olsen WR, Hoffman GL. The continuing development of the technique of thyroidectomy. *Surgery* 1973;73:913–27.

甲狀腺手術中喉返神經之解剖學變異 — 如何應用術中神經監測器來辨識及處理

江豐裕^{1,2} 盧奕丞³ 陳慧君⁴ 陳秀雅³ 蔡承靜³ 蕭璧容^{2,5} 李家和^{1,2} 吳哲維^{6,7}

高雄醫學大學附設醫院¹ 耳鼻喉科³ 麻醉科⁴ 護理部⁵ 內科部⁵ 內分泌新陳代謝科

高雄市立小港醫院⁶ 耳鼻喉科

高雄醫學大學 醫學院² 醫學系⁷ 臨床醫學研究所

喉返神經麻痺是甲狀腺手術後最常見且嚴重的併發症。術中常規目視確認喉返神經位置已被證實可以降低神經傷害的機率；儘管目視確認神經已被認定是標準的手術步驟，但是並不能完全保證不會有術後神經麻痺的情況發生。喉返神經之解剖學變異，例如喉外分支，走向扭曲偏移，神經分支與下甲狀腺動脈糾纏，以及非返喉神經等，是容易導致目視誤認而造成神經傷害的潛在原因。因此在甲狀腺手術中確認喉返神經功能及解剖上的完整性是手術安全的必要條件。本篇文章中，我們回顧了關於喉返神經變異的文獻。同時我們也以高解析度的手術照片來示範如何應用術中神經監測器來辨識及處理喉返神經解剖學變異的情形，此類資訊可協助甲狀腺外科醫師在手術中面對處理各種變異狀況。喉返神經之解剖學變異並無法在術前預測，而且神經可能受傷的機會較高。術中若能應用神經偵測器將喉返神經確實的辨識出來，那麼因目視誤認而造成神經受傷的情形將會大大降低。

關鍵詞：解剖學變異，術中神經監測器，喉部肌電圖，喉返神經，甲狀腺手術

(高雄醫誌 2010;26:575-83)

收文日期：99年7月19日

接受刊載：99年7月28日

通訊作者：吳哲維醫師

高雄醫學大學附設醫院耳鼻喉科

高雄市自由一路100號