

## Cocaine- and amphetamine-regulated transcript immunoreactive nerve fibres in the mucosal layer of the canine gastrointestinal tract under physiological conditions and in inflammatory bowel disease

A. RYCHLIK, S. GONKOWSKI, M. NOWICKI, J. CALKA

Faculty of Veterinary Medicine, University of Warmia and Mazury in Olsztyn, Olsztyn, Poland

**ABSTRACT:** The objective of this study was to determine the effect of canine inflammatory bowel disease (IBD) on the density of cocaine- and amphetamine-regulated transcript (CART) immunoreactive nerve fibres in the mucosa of different sections of the gastrointestinal tract. Fibre density was analysed in mucosal specimens from the duodenum, jejunum and descending colon of healthy dogs and patients with inflammatory bowel disease of varying intensity. Nervous fibres were stained in single-cell immunofluorescence assays. The density of CART-immunoreactive fibres was determined using a semi-quantitative approach by counting the number of fibres in the field of view (0.1 mm<sup>2</sup>). An increase in the density of CART-immunoreactive fibres was observed in dogs with moderate and severe IBD in comparison with healthy subjects. The results suggest that the presence of CART in enteric nerve fibres could play a role in the pathogenesis and development of canine IBD.

**Keywords:** immunohistochemistry; digestive tract; nervous system; dogs

Canine inflammatory bowel disease (IBD) encompasses a group of chronic enteropathies characterised by persistent or recurring gastric symptoms with unknown aetiology that are related to histopathological changes in the mucosa of the small intestine and the colon in the form of cellular infiltration in the mucosal lamina propria (Allenspach and Gaschen 2003). According to numerous sources, the oversensitivity of intestinal lymphatic tissue to intestinal antigens is a key contributor to the disease. In IBD inflammation of the intestinal tract results from the activation of T helper lymphocytes, B lymphocytes and the production of pro-inflammatory cytokines (Mancho et al. 2010; Simpson and Jergens 2011; Jergens and Simpson 2012). The classification of IBD is determined by the predominant type of inflammatory cells in the lamina propria of the intestinal mucosa. The pathogenesis of IBD involves various factors, and has not yet been fully elucidated. The predominant factors involved in canine

inflammatory bowel disease include bacterial and environmental factors, genetic predispositions of selected breeds, allergens and side effects of particular drugs (Bhatia and Tandon 2005; Allenspach et al. 2007; Simpson and Jergens 2011; Jergens and Simpson 2012). Recent research has demonstrated that substances acting as neurotransmitters and/or neuromodulators of the enteric nervous system (ENS) play an important role in the pathogenesis of IBD (Vasina et al. 2006; Gonkowski and Calka 2012). One such substance is the cocaine- and amphetamine-regulated transcript (CART) peptide (Ekblad 2006; Gonkowski et al. 2009a; Gonkowski et al. 2009b; Gonkowski et al. 2013a).

The CART peptide has been isolated from the sheep hypothalamus (Spiess et al. 1981). Its name is derived from the rapid increase in the levels of its mRNA in the rat striatum after the administration of cocaine and/or amphetamine (Douglass et al. 1995). It is believed that CART is the key neuro-

transmitter regulating satiety via cholecystokinin and leptin (Heldsinger et al. 2012).

To date, the presence of CART was reported in the enteric nervous system of humans (Gunnarsdottir et al. 2007; Gonkowski et al. 2009b; Gonkowski et al. 2013a) and other mammalian species (Ekblad 2006; Wierup et al. 2007; Gonkowski et al. 2009a), but its functions in the stomach and intestines have not been fully elucidated. The body of existing research has demonstrated that CART can inhibit hydrochloric acid secretion in the stomach (Okumura et al. 2000) and influence colonic motility (Tebbe et al. 2004). Intracerebroventricular (i.c.v.) administration of CART inhibits gastric emptying, leads to pentagastrin-induced secretion of hydrochloric acid and stimulates colonic motility (Ekblad 2006). The co-localisation of CART with more extensively studied neurotransmitters and/or neuromodulators such as vasoactive intestinal peptide (VIP), nitric oxide (NO) and calcitonin gene-related peptide (CGRP) could indicate that these substances have similar functions (Ekblad 2006; Gunnarsdottir et al. 2007; Wierup et al. 2007; Gonkowski et al. 2013a). Changes in CART expression in the enteric nervous system in pathological states have not been the subject of extensive research and to the best of our knowledge have been investigated only in humans and domestic pigs. It has been demonstrated that inflammatory states affect the number of CART-positive nerve fibres (Gunnarsdottir et al. 2007; Gonkowski et al. 2009b) and that CART expression is correlated with prognosis in small intestinal carcinoid tumours in humans (Landerholm et al. 2012). However, the role of CART in canine IBD has not been studied to date. In view of the above, the objective of this study was to determine the number of CART-positive nerve fibres in the mucosa of different sections of the canine gastrointestinal tract under physiological conditions and in IBD with the aim of expanding our knowledge of the functions of CART peptides and pathological processes associated with the disease.

## MATERIAL AND METHODS

The study was performed on 28 German shepherd hybrids of both sexes with body weights of 15–25 kg, aged six to 10 years. The control group comprised seven healthy dogs. The animals classified in this group came from a Shelter in Olsztyn and showed no clinical signs of disease or deviations from ref-

erence values in IBD diagnostic tests. The experimental groups consisted of patients admitted to the Veterinary Clinic of the University of Warmia and Mazury in Olsztyn. The experiment was approved by the Local Ethics Committee for Animal Experimentation in Olsztyn (Decision No. 47/2009/DTN). Dogs from all groups were selected for the experiment based on the results of clinical, laboratory, endoscopic and histopathological examinations of duodenal, jejunal and colonic mucosal sections.

Patients with suspected IBD were subjected to biochemical, radiological, parasitological, bacteriological and mycological faeces tests as well as provocative food tests to rule out other diseases accompanied by chronic diarrhoea.

Dogs with diagnosed IBD were divided into groups according to the intensity of clinical symptoms based on canine inflammatory bowel disease activity index (CIBDAI) scores:

- Group I: mild IBD, CIBDAI score of four to five points, histopathological grade “+”, seven dogs
- Group II: moderate IBD, CIBDAI score of six to eight points, histopathological grade “++”, seven dogs
- Group III: severe IBD, CIBDAI score of 10–16 points, histopathological grade “+++”, seven dogs

Samples for immunohistochemical analyses were collected from experimental and control group animals during gastroscopy or colonoscopy performed with the use of Olympus FB-24U-1 biopsy forceps with a diameter of 2.5 mm and Olympus FB-50U-1 biopsy forceps with a diameter of 3.7 mm. Three specimens were collected from every investigated section of the gastrointestinal tract. These were fixed by immersion in 4% buffered paraformaldehyde solution for 15 min. Tissues were rinsed in phosphate buffer (pH of 7.4) for three days, and the buffer was replaced daily. The specimens were transferred to 18% phosphate-buffered sucrose solution with a temperature of 4 °C. Frozen sections of 10 µm were cut using a Microm cryostat (HM525, Walldorf, Germany), placed on gelatinised microscopic slides and subjected to single-cell immunofluorescence staining in accordance with the method reported by Gonkowski et al. (2013b). The specimens were dried for 45 min at room temperature and rinsed three times in buffered NaCl solution (PBS, 0.1 mol, pH 7.4) for 15 min. They were then incubated in a blocking solution containing 10% goat serum, 0.1% bovine serum albumin, 0.01% NaN<sub>3</sub>, Triton X-100 and thiomersal in PBS for one

doi: 10.17221/8383-VETMED

hour. The specimens were subsequently kept in a moist chamber at room temperature. After rinsing in NaCl solution (PBS, 0.1 mol, pH 7.4), anti-CART antibody (mice, R&D System, Minneapolis, MN, USA, cat. No. MAB 163, working dilution 1 : 10000) was applied to the specimens. After incubation with the primary antibody (overnight) and three washes, the sections were incubated with the FITC-conjugated secondary antibody (goat, ICN Biomedicals, working dilution 1 : 800) for one hour at room temperature. The specimens were rinsed and covered with cover slips with the use of glycerol solution and PBS (1 : 2, pH 7.4). Stained sections were evaluated under a OLYMPUS BX51 epifluorescence microscope equipped with filters. The density of CART-immunoreactive fibres was determined using a semi-quantitative approach by counting the number of fibres in the field of view (0.1 mm<sup>2</sup>). Fibres were counted in four fields of view in three specimens from every analysed section of the gastrointestinal tract (duodenum, jejunum and colon). A total of 36 fields of view for every examined section were evaluated per substance in each patient. The evaluated fields were separated by a minimum distance of 100 µm to avoid repeated counts. The results were averaged and presented as mean values ± standard deviation (SD). A pre-absorption test was carried out to check the specificity of primary antibodies. Depending on the antibody, 2–10 µg of synthetic peptide were added to 100 µl of the respective solution diluted to a working solution. The mixture was incubated for 24 h at 4 °C and used to stain sections of the small intestine and the colon. The applied treatment completely eliminated specific

staining during tissue incubation with the prepared antibodies.

The significance of differences between groups was determined using the Kruskal-Wallis test at  $P < 0.05$  (significant) and  $P < 0.01$  (highly significant). The results were processed in the Statistica 9.1 application (StatSoft Inc.).

## RESULTS

An insignificant increase in the number of CART-immunoreactive fibres in duodenal mucosa and a minor drop in the number of fibres in jejunal and colonic mucosa were reported in Group I relative to control (Figure 1). In the control group, the number of fibres reached 0.698 in duodenal mucosa, 0.690 in jejunal mucosa and 0.817 in colonic mucosa (Table 1). In patients with mild IBD (Group I), the number of fibres was determined at 0.698, 0.646 and 0.642 in the analysed sections of the gastrointestinal tract, respectively (Table 1). In Groups II and III, a higher number of CART-immunoreactive fibres was noted in duodenal, jejunal and colonic mucosa in comparison with control (Figure 1). In dogs with moderate IBD, the number of analysed fibres was determined to be 0.801 in duodenal mucosa, 0.940 in jejunal mucosa and 0.827 in colonic mucosa. In patients with severe IBD, the number of CART-immunoreactive fibres was determined to be 1.059, 1.031 and 0.849 in duodenal, jejunal and colonic mucosa, respectively (Table 1).

A significant difference in the number of CART-immunoreactive fibres in duodenal mucosa was observed between dogs with mild IBD (Group I) and patients with a severe form of the disease (Group III).

Table 1. The numbers of CART-immunoreactive nerve fibers per observation field in the mucosal layer of the duodenum, jejunum and descending colon in animals of the control Group (C) and dogs suffering from mild (I), moderate (II) and severe (III) IBD

		Group C	Group I	Group II	Group III
Duodenum	$\bar{x}$	0.678	0.698 <sup>c</sup>	0.801	1.059 <sup>b</sup>
	SD	0.21	0.07	0.20	0.28
Jejunum	$\bar{x}$	0.690 <sup>c</sup>	0.646 <sup>D</sup>	0.940	1.031 <sup>aB</sup>
	SD	0.19	0.16	0.10	0.11
Colon	$\bar{x}$	0.817	0.642	0.827	0.849
	SD	0.32	0.18	0.15	0.32

<sup>a</sup>differs significantly from control; <sup>b</sup>differs significantly from group I; <sup>c</sup>differs significantly from group III Kruskal-Wallis test;  $P < 0.05$  – lower case letter,  $P < 0.01$  – upper case letter

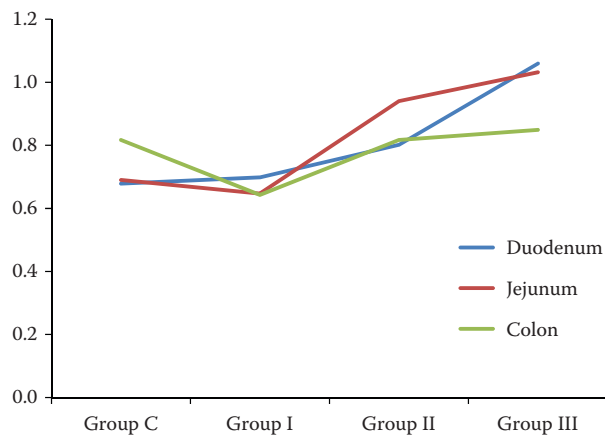


Figure 1. Numbers of CART-immunoreactive fibres in different sections of the gastrointestinal tract in healthy dogs and patients with IBD

In jejunal mucosa, the number of the analysed fibres differed to a highly significant degree between Group I and Group III dogs. Significant differences in the number of CART-immunoreactive fibres in duodenal mucosa and highly significant differences in the number of CART-positive fibres in jejunal mucosa were observed between Group III and control (Table 1). The density of CART-immunoreactive fibres in the analysed sections of the gastrointestinal tract of healthy dogs and patients with IBD is shown in Figures 2 and 3.

## DISCUSSION

The present investigation shows that the density of CART-LI nerve fibers in the mucosal layer of canine duodenum, jejunum and descending colon

is very low. These observations are in agreement with previous studies on other species (Ekblad 2006; Gonkowski et al. 2009a; Gonkowski et al. 2009b), where mucosal nerve structures within intestinal mucosa were also noted sporadically, and the majority of CART-LI nerves were located mainly in the circular layer of the gastrointestinal tract (Gonkowski et al. 2009a; Gonkowski et al. 2009b). Such localisation of nervous structures immunopositive to CART strongly suggests that this peptide is mostly involved in the regulation of gastric and intestinal motility. This idea is further supported by the previous observation that CART co-localises with other active substances, such as nitric oxide synthase (NOS) or vasoactive intestinal polypeptide (VIP), known to be important regulators of motility in the same intestinal nervous structures (Gonkowski et al. 2013a). Therefore, it is likely that CART acts as a neuromodulator of the above-mentioned factors. Moreover, it is known that CART affects colonic motility (Tebbe et al. 2004) and can reduce the nitric oxide-induced relaxation of intestinal muscles (Ekblad et al. 2003). Nevertheless, until now the exact mechanism through which CART exerts its influence on gastrointestinal motility remains unknown, as previous studies have not shown any direct effect of this peptide on muscular contractility (Ekblad et al. 2003). It is also known that CART is involved in secretory functions of the gastrointestinal tract; namely, it can reduce gastric acid secretion (Okumura et al. 2000). Moreover, previous studies have reported that CART is influenced by inflammatory processes (Gonkowski et al. 2009b), which can suggest both the involvement of this peptide in the adaptation of

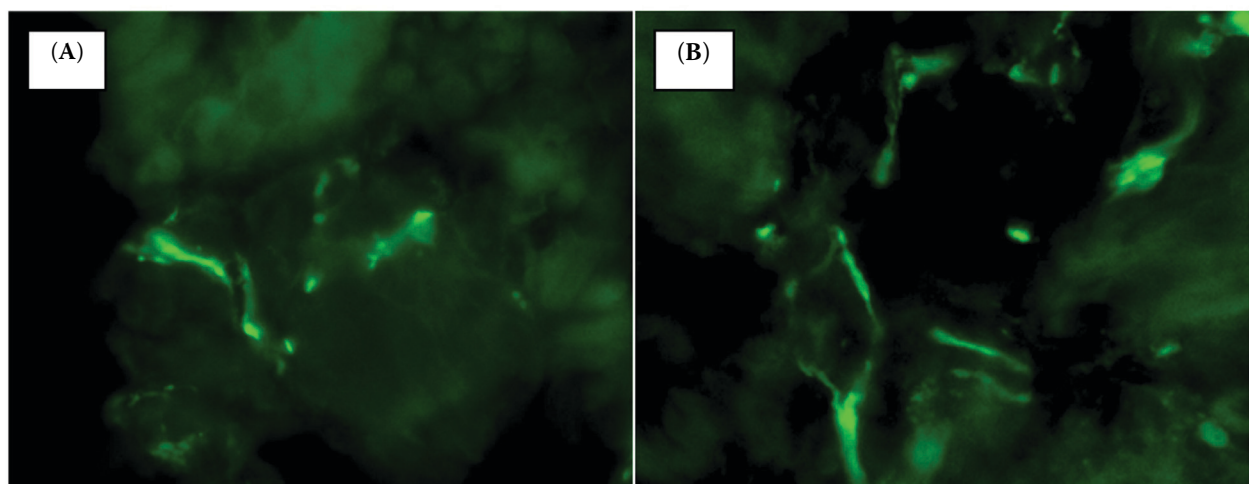


Figure 2. CART-immunoreactive fibres in canine duodenal mucosa. A = group I, B = group III ( $\times 400$  magnification)

doi: 10.17221/8383-VETMED

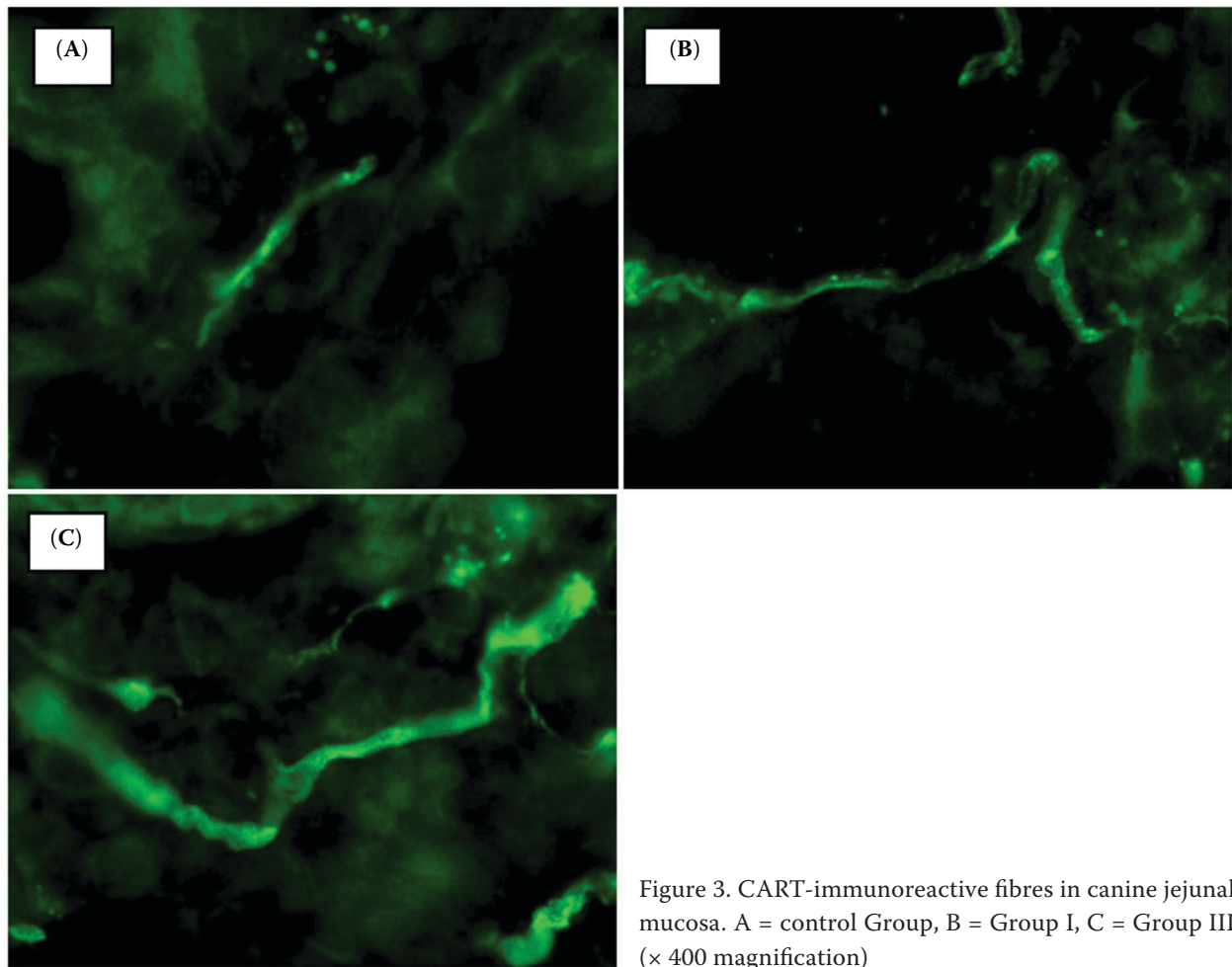


Figure 3. CART-immunoreactive fibres in canine jejunal mucosa. A = control Group, B = Group I, C = Group III ( $\times 400$  magnification)

the nervous system to pathological agents, as well as neuroprotective functions. The present study appears to confirm these notions.

The obtained results show that IBD elicits detectable changes in the number and appearance of CART-LI mucosal fibres of the canine digestive tract. These changes depend on both the section of the intestine and the intensity of pathological processes. Differences between various segments of the gastrointestinal tract could suggest that CART plays different roles across the digestive system. The above trend was particularly visible in dogs with mild IBD, where the number of CART-LI fibres, in comparison with the control group, increased in the mucosal layer of the duodenum, and decreased in the jejunum and descending colon, as well as in animals suffering from severe IBD, where the illness caused changes only within the small intestine (Figure 1).

It should be pointed out that the IBD-induced changes observed during the present experiment may result from various types of processes.

Fluctuations in the density of CART-LI nerves could be connected with modifications of the synthesis of this peptide within the nervous system at the transcriptional, translational or metabolic level. On the other hand, the observed changes may result from variations in intraneuronal transport of CART from perikarya to nerve endings connected with the higher need for this peptide at synapses.

The exact causes of the fluctuation in the density of the CART-LI mucosal layer during IBD, as well as the functions of this peptide in the intestine under pathological stimuli are still unknown. The obtained results may be due to the direct effect of inflammatory processes, transduction of pain signals or changes in intestinal secretory functions. Moreover, CART is an endothelin-induced vasoconstrictor (Iloff et al. 2012), and it could play an important role in the pathogenesis of IBD in other species, systemic vascular inflammation and intestinal ischaemia (Murch et al. 1992). The fluctuations in CART expression observed during the present investigation could be connected with the

clearly visible macroscopic and histological changes typical in dogs suffering from IBD, especially moderate and severe forms of the disease. Macroscopic images revealed changes in the surface structure of intestinal mucosa, including increased fragility and granulation, folding, frequent extravasations and increased susceptibility to bleeding. In those groups, histopathological analyses revealed changes in the size and shape of intestinal villi and glands in the analysed sections. These changes could probably be attributed to impaired recovery of small intestinal and colonic mucosa in dogs with moderate and severe IBD.

On the other hand, the changes observed during the present study may arise from the well-described anorectic and satiety-regulating properties of CART (Kristensen et al. 1998), and a decrease or loss of appetite is an important clinical symptom of IBD, in particular in patients with a severe form of the disease. In dogs with IBD, loss of appetite and/or anorexia leads to weight loss. Nakhate et al. (2010) reported increased appetite and body weight in healthy rats after the injection of anti-CART antibodies in the cerebral cortex. Therefore, the increase in the number of CART-LI fibres observed during this study in dogs with moderate and severe IBD could be attributed to the loss of appetite and, consequently, weight loss of the dogs.

The increase in the number of CART-LI intestinal mucosal fibres noted both in dogs with moderate and severe IBD during the present investigation, as well as in previous studies on humans (Gonkowski et al. 2009b) may suggest that CART is also involved in neuroprotective and/or adaptive processes within intestinal nerves in response to pathological stimuli.

In conclusion, the present study shows that IBD causes changes in the density of CART-LI nerves in the mucosal layer of the canine digestive tract, suggesting a role for this peptide during intestinal inflammatory processes. Nevertheless, the exact roles of CART within the intestine of the dog both in physiological conditions and during inflammatory bowel diseases remain unknown and require further experiments.

## REFERENCES

- Allenspach K, Gaschen F (2003): Chronic intestinal diseases in the dog: a review. *Schweizer Archiv für Tierheilkunde* 145, 209–219.
- Allenspach K, Wieland B, Grone A, Gaschen F (2007): Chronic enteropathies in dogs: Evaluation of risk factors for negative outcome. *Journal of Veterinary Internal Medicine* 21, 700–708.
- Bhatia V, Tandon RK (2005): Stress and the gastrointestinal tract. *Journal of Gastroenterology and Hepatology* 20, 332–339.
- Douglass J, McKinzie AA, Couceyro P (1995): PCR differential display identifies a rat brain mRNA that is transcriptionally regulated by cocaine and amphetamine. *Journal of Neuroscience* 15, 2471–2481.
- Ekblad E (2006): CART in the enteric nervous system. *Peptides* 27, 2024–2030.
- Ekblad E, Kuhar M, Wierup N, Sundler F. (2003): Cocaine- and amphetamine- regulated transcript: distribution and function in rat gastrointestinal tract. *Neurogastroenterology & Motility* 15, 545–557.
- Gonkowski S, Calka J (2012): Changes in Pituitary Adenylate Cyclase-Activating Peptide 27-Like Immunoreactive Nervous Structures in the Porcine Descending Colon during Selected Pathological Processes. *Journal of Molecular Neuroscience* 48, 777–787.
- Gonkowski S, Burlinski P, Skobowiat C, Majewski M, Arciszewski MB, Radziszewski P, Calka J. (2009a): Distribution of cocaine- and amphetamine-regulated transcript-like immunoreactive (CART-LI) nerve structures in the porcine large intestine. *Acta Veterinaria Hungarica* 57, 509–520.
- Gonkowski S, Kaminska B, Burlinski P, Kroll A, Calka J (2009b): The influence of drug-resistant ulcerative colitis on the number of cocaine- and amphetamine-regulated transcript peptide-like immunoreactive (CART-LI) mucosal nerve fibres of the descending colon in children. *Przegląd Gastroenterologiczny* 4, 147–151.
- Gonkowski S, Kaminska B, Landowski P, Calka J. (2013a): Immunohistochemical distribution of cocaine- and amphetamine-regulated transcript peptide-like immunoreactive (CART-LI) nerve fibres and various degree of co-localization with other neuronal factors in the circular muscle layer of human descending colon. *Histology and Histopathology* 28, 851–858.
- Gonkowski S, Rychlik A, Calka J (2013b): Pituitary adenylate cyclase activating peptide-27-like immunoreactive nerve fibers in the mucosal layer of canine gastrointestinal tract in physiology and during inflammatory bowel disease. *The Bulletin of the Veterinary Institute in Pulawy* 57, 375–380.
- Gunnarsdottir A, Wierup N, Larsson LT, Kuhar MJ, Ekblad E (2007): CART-peptide immunoreactivity in enteric nerves in patients with Hirschsprung's disease. *European Journal of Pediatric Surgery* 17, 184–189.
- Heldsinger A, Lu Y, Zhou SY, Wu X, Grabauskas G, Song I, Owyang C (2012): Cocaine- and amphetamine-regulated

doi: 10.17221/8383-VETMED

- transcript is the neurotransmitter regulating the action of cholecystokinin and leptin on short-term satiety in rats. *American Journal of Physiology. Gastrointestinal and Liver Physiology* 303, G1042–G1051.
- Iliff JJ, Alkayed, NJ, Glosiani KJ, Traystman RJ, West GA (2005): Cocaine- and amphetamine-regulated transcript (CART) peptide: A vasoactive role in cerebral circulation. *Journal of Cerebral Blood Flow and Metabolism* 25, 1376–1385.
- Jergens AE, Simpson KW (2012): Inflammatory bowel disease in veterinary medicine. *Frontiers in Bioscience (Elite Ed)* 4, 1404–1419.
- Kristensen P, Judge ME, Thim L, Ribel U, Christjansen KN, Wulff BS, Clausen JT, Jensen PB, Madsen OD, Vrang N, Larsen PJ, Hastrup S (1998): Hypothalamic CART is a new anorectic peptide regulated by leptin. *Nature* 393, 72–76.
- Landerholm K, Shcherbina L, Falkmer SE, Järhult J, Wierup N (2012): Expression of cocaine- and amphetamine-regulated transcript is associated with worse survival in small bowel carcinoid tumors. *Clinical Cancer Research* 18, 3668–3676.
- Mancho C, Sainz A, Garca-Sancho M, Villaescusa A, Teodoro M, Rodriguez-Franco, F. (2010): Detection of perinuclear antineutrophil cytoplasmic antibodies and antinuclear antibodies in the diagnosis of canine inflammatory bowel disease. *Journal of Veterinary Diagnostic Investigation* 22, 553–558.
- Murch SH, Braegger CP, Sessa WC, MacDonald TT (1992): High endothelin-1 immunoreactivity in Crohn's disease and ulcerative colitis. *Lancet* 339, 381–385.
- Nakhate KT, Kokare DM, Singru PS, Taksande AG, Kotwal SD, Subhedar NK (2010): Hypothalamic cocaine- and amphetamine-regulated transcript peptide is reduced and fails to modulate feeding behavior in rats with chemically-induced mammary carcinogenesis. *Pharmacology Biochemistry and Behavior* 97, 340–349.
- Okumura T, Yamada H, Motomura W, Kohgo Y (2000): Cocaine-amphetamine-regulated transcript (CART) acts in the central nervous system to inhibit gastric acid secretion via brain corticotropin-releasing factor system. *Endocrinology* 141, 2854–2860.
- Simpson KW, Jergens AE (2011): Pitfalls and progress in the diagnosis and management of canine inflammatory bowel disease. *Veterinary Clinics of North America Small Animal Practice* 41, 381–398.
- Spiess J, Villarreal J, Vale W (1981): Isolation and sequence analysis of a somatostatin-like polypeptide from ovine hypothalamus. *Biochemistry* 20, 1982–1988.
- Tebbe JJ, Ortman E, Schumacher K, Mönnikes H, Kobelt P, Arnold R, Schäfer MK (2004): Cocaine- and amphetamine-regulated transcript stimulates colonic motility via central CRF receptor activation and peripheral cholinergic pathways in fed, conscious rats. *Neurogastroenterology and Motility* 16, 489–496.
- Vasina V, Barbara G, Talamonti L, Stanghellini V, Corinaldesi R, Tonini M, De Ponti F, De Giorgio R (2006): Enteric neuroplasticity evoked by inflammation. *Autonomic Neuroscience: Basic and Clinical* 126–127, 264–272.
- Wierup N, Gunnarsdóttir A, Ekblad E, Sundler F (2007): Characterisation of CART-containing neurons and cells in the porcine pancreas, gastro-intestinal tract, adrenal and thyroid glands. *BMC Neuroscience* 8, 1471–2202.

Received: 2014–02–07

Accepted after corrections: 2015–07–07

## Corresponding Author:

Andrzej Rychlik, University of Warmia and Mazury in Olsztyn, Faculty of Veterinary Medicine, ul. Oczapowskiego 14, 10-957 Olsztyn, Poland

E-mail: rychlik@uwm.edu.pl