

CONTINUING EDUCATION PROGRAM: FOCUS...

## Low-grade gliomas: The challenges of imaging



R. Guillevin\*, G. Herpe, M. Verdier, C. Guillevin

*Laboratoire DACTIM, service de radiologie, université de Poitiers, centre hospitalier universitaire de Poitiers, 2, rue de la Milétrie, 86021 Poitiers, France*

### KEYWORDS

MRI;  
Spectroscopy;  
Perfusion imaging;  
Low-grade gliomas;  
Therapeutic  
follow-up

**Abstract** WHO grade II gliomas are a major challenge for magnetic resonance imaging (MRI) due to their delayed anaplastic transformation. Today it is possible to individually characterize tumor progression from diagnosis to anaplastic transformation based on the many parameters identified in studies in the literature and the possibility of integrating these data into mathematical models. Early identification of negative morphological and metabolic factors, as well as treatment follow-up, help identify predictive factors of tumor progression, as well as determine treatment response to adapt management of this disease.

© 2014 Éditions françaises de radiologie. Published by Elsevier Masson SAS. All rights reserved.

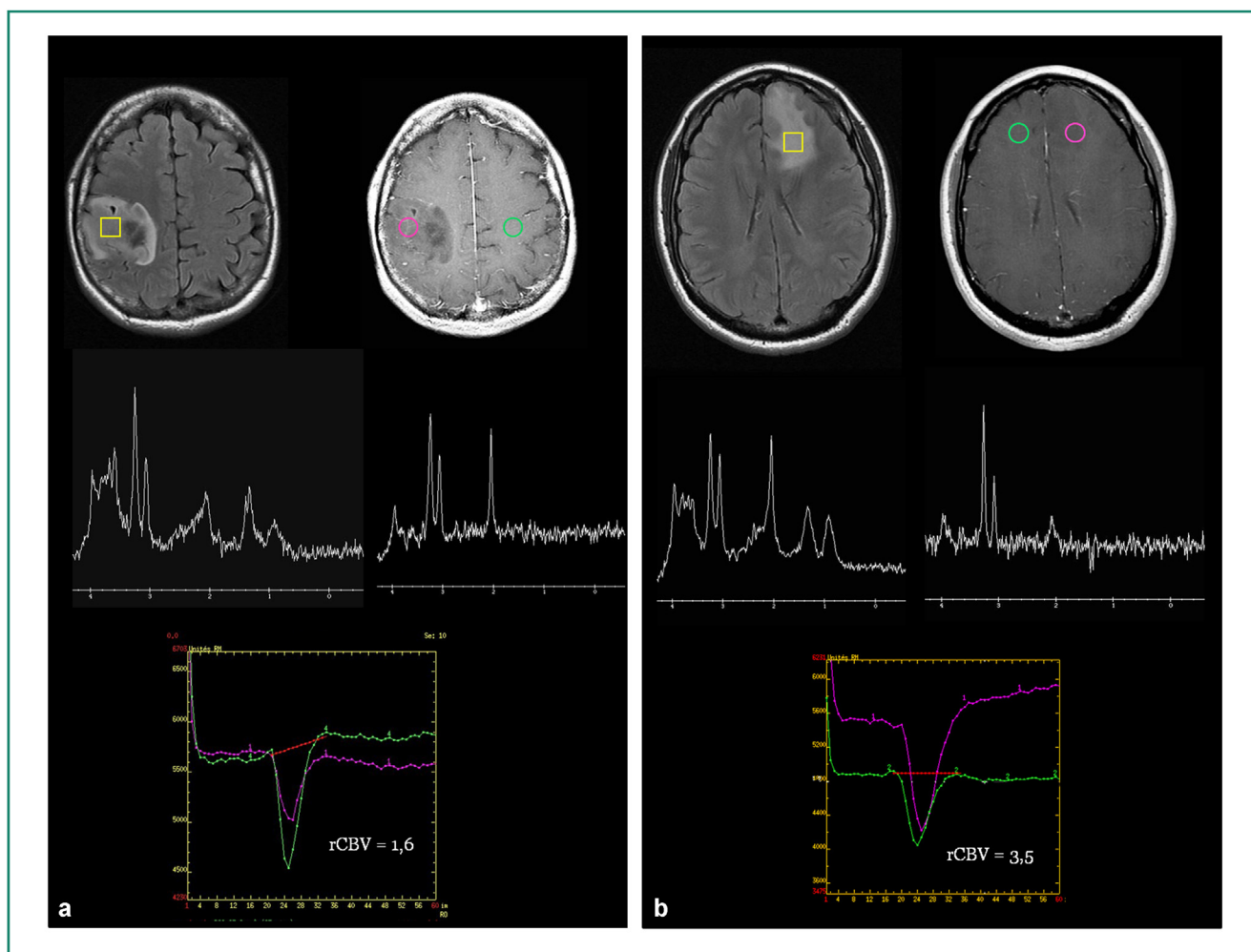
At present MRI is the first line imaging technique for the non-invasive exploration of intracranial tumor progression. Nevertheless, the sensitivity and specificity of existing MRI protocols are limited [1,2]. According to the WHO classification, grade II gliomas, also called low-grade gliomas (LGG), express atypical nuclei and inevitably progress at a rate that varies from one case to another. In the last decade, the pre-therapeutic characterization of these tumors has improved significantly thanks to advances in imaging techniques. Thus, MR spectroscopy (which is essentially protonic) and dynamic perfusion imaging have helped improve the specificity and sensitivity of MRI for the diagnosis and follow-up of gliomas (Fig. 1). Tumor volume, relative cerebral blood volume and MR spectroscopy results have also provided predictive factors of disease progression or response to treatment, while other MRI parameters are correlated to molecular profiles.

\* Corresponding author. Tel.: +33 549 443 911.  
E-mail address: [remy.guillevin@chu-poitiers.fr](mailto:remy.guillevin@chu-poitiers.fr) (R. Guillevin).

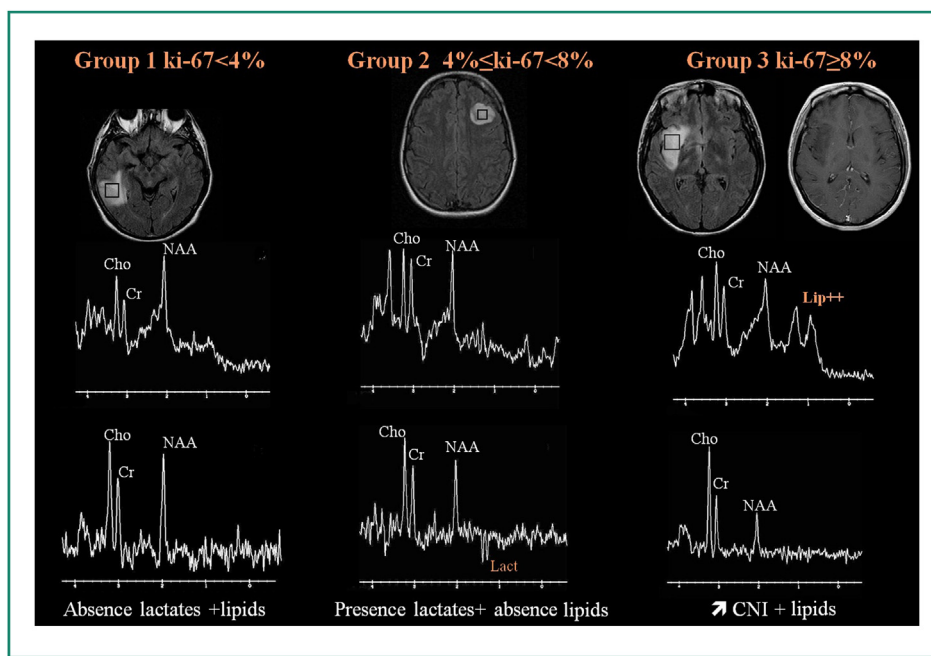
## Improving the diagnostic accuracy: how aggressive is a WHO grade II (OK?) tumor?

From diagnosis to prognosis. Diffuse low-grade gliomas (WHO grade II gliomas, LGG) are heterogenous on MRI. These infiltrating tumors have ill-defined margins on T2-weighted (hyperintense) as well as T1-weighted (hypointense) images and usually have no contrast enhancement following gadolinium injection. When enhancement occurs, in 10 to 50% of the cases depending on the series, it is moderate and only in a small portion of the tumor. The prognostic value of this event is still a subject of debate [3,4]. Only clearly nodular-shaped tumors and time-progressive tumor enhancement have been shown to have a negative prognostic value [5]. Moreover, there is significant intraobserver variability as well as an inter-institutional heterogeneity of parameters depending on the magnetic field and the types of sequences obtained. T1-weighted spin echo sequences have been shown to be better than gradient-echo sequences [6,7]. Recent studies have shown that diffusion imaging with ADC variations is better at identifying anaplastic

transformation in progressive LGG [8]. The 1p/19q co-deletion can be confirmed by quantifying texture [9]. Several correlations have been established between proton spectroscopy and pathology, immunohistology and molecular biology, and some of these criteria are considered to be predictive of anaplastic transformation of LGG. Thus, there is a correlation with the Cho/Cr index (all levels). More recently, specific spectral patterns for a range of Ki-67 values have been established for LGG [10]. Thus, the presence of increased lactate resonance, indicative of underlying anaerobiosis, is predictive of a Ki-67 index of 4 to 8% (Fig. 2). Later, membrane alterations result in resonance of mobile lipids, which is correlated to atypical cells and predictive of a Ki-67 index of above 8% (Figs. 1 and 2). Thus, the results of "spectroscopic" analysis suggest that there is a critical Ki-67 threshold value. Similarly, indirect identification of the IDH mutation based on 2-hydroxyglutarate resonance on MR spectroscopy using separation spectral editing, a tool that is now available in some centers, has diagnostic and predictive value [11]. Multinuclear MR spectroscopy, and in particular  $^{31}\text{P}$  phosphorus spectroscopy, can also be used to investigate



**Figure 1.** Is this a low-grade glioma? (a) Heterogeneous gadolinium enhanced right parietal rolandic tumor. On MR spectroscopy, CNI is moderately increased with the presence of lactate resonance. The rCBV is 1.6. WHO grade II glioma with Ki-67 index = 4%. (b) Homogenous frontal lobe tumor on all sequences, no gadolinium enhancement. The CNI is much higher here with mobile lipids and lactate resonance and the rCBV is 3.5. WHO grade II glioma, Ki-67 index 12%.



**Figure 2.** What is the sub-grade? The spectral pattern predicts a range of values for the Ki-67 index. Lactate resonance predicts a Ki-67 index of between 4 and 8%, while mobile lipid resonance predicts a Ki-67 index above 8%.

the natural history of LGG. A 2012 study [12], showed that the PME/PDE ratio and the pHi value were elevated in LGG with a Ki-67 above 8%, results that have already been shown to be pro-anaplastic factors in experimental studies [13].

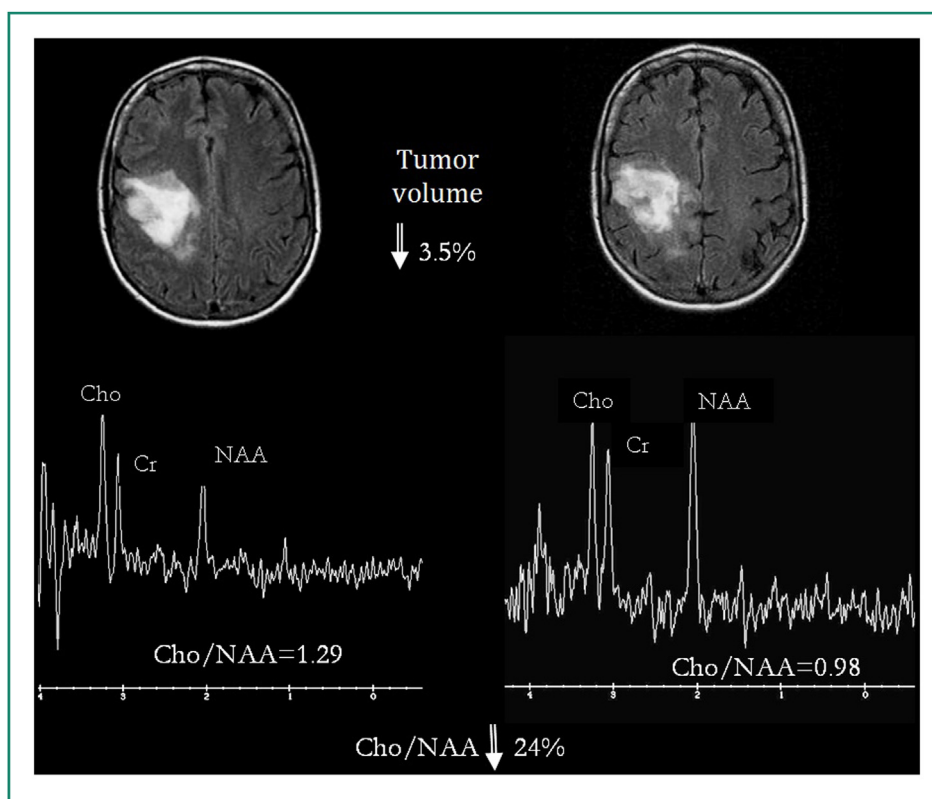
## Metabolic changes and increased perfusion

Numerous studies have shown the value of perfusion imaging for the initial characterization and follow-up of LGG. An increase in rCBV values precedes T1-weighted post-gadolinium tumor enhancement, sometimes by a few months [14]. Initial rCBV values above 1.7 were negatively correlated to survival and predictive of progression-free survival that was 4 to 5 times lower than in patients with rCBV values below 1.7 [15,16]. However, discrimination between oncotypes remains controversial. Indeed, although a certain difference has been found in the rCBV between oligodendrogliomas and astrocytomas in some studies, it was not significant and varied considerably depending on the study [17–19]. This, as well as the poor reproducibility of rCBV values between 1.5 and 3 Tesla machines, may represent a potential weakness of perfusion imaging, which is too often performed alone as an “advanced imaging technique” (i. e. without MR spectroscopy) [20]. Capillary permeability, which can be determined on T1- and T2- weighted perfusion imaging ( $k_{\text{Trans}}$  and  $K_2$ ), could provide early proof of progression of low-grade gliomas [21]. The maximum rCBV value was positively correlated with choline resonance, which increased with tumor progression [22]. Our team showed that the CNI, as well as Lac/Cr and Lip/Cr ratios, were independent predictive factors of the maximum rCBV [16]. Moreover, these two ratios discriminated between patient survival in the two groups based on the rCBV values established by Law et al. This study, like others,

emphasizes the importance of combining proton MR spectroscopy and dynamic perfusion imaging, two complementary techniques, for the initial assessment and follow-up of low-grade gliomas.

## Post-therapeutic follow-up

For several years, long-term volumetric measurement of tumor size has been considered to be the simple, most effective tool for treatment follow-up. The average transverse diameter (ATD) is determined on T2-weighted images (most often FLAIR images). However, this morphological parameter must be monitored for at least six months to obtain a reliable indication of tumor progression. Moreover, some studies [23,24] have suggested that chemotherapy could induce metabolic alterations in the tumor with no perceptible changes in morphological features or standard MRI signals. Thus, the response to chemotherapy could be incorrectly considered to be lacking or delayed, because it is evaluated by morphological imaging only, which is usually the case. Proton MR spectroscopy has been shown to be useful for the short-term assessment of chemotherapy, once again confirming its complementarity with standard MRI [25,26]. Thus, one study [27] showed that modifications could be observed on monovoxel proton MR spectroscopy as early as the first month after treatment with temozolomide, while changes in tumor volume were slight and barely perceptible by the radiologist. An easily quantifiable, significant and concomitant decrease in Cho/Cr and Cho/Naa ratios was observed in responders, indicating the direct metabolic effect of temozolomide on tumor anaplasia [28]. Furthermore, in patients with secondary escape from treatment during the study, an event that is clearly seen on the treatment follow-up curve (Fig. 3), preceded the change in



**Figure 3.** Spectroscopy and treatment follow-up. An example of a temozolomide treated grade II glioma. Three month follow-up assessment. Despite a slight decrease in tumor volume which is barely detectable with volumetric analysis, the comparison of the CNI and Cho/Cr ratios shows clear, objective variations corresponding to a therapeutic response.

tumor volume by one or two months. These data suggest that a change in treatment could be planned. Finally, after three months of treatment, it is possible to predict a tumor response (relative mean decrease in Cho/CR), or an "escape from treatment" at 14 months (relative mean decrease in Cho/CR and Cho/Naa). This correlation between tumor volume and MR spectroscopy, in particular over time, seems to be particularly important with temozolomide, due to:

- the importance of this drug in the treatment options of LGG as well as;
- the wide range of response rates reported in numerous studies in the literature [29,30].

Another difficulty in the follow-up of low-grade gliomas is evaluation of the results of radiation therapy. Standard MRI often fails to distinguish between radiation necrosis and tumor recurrence. "Soap bubble" or especially "swiss cheese" enhancement on T1-weighted gadolinium enhanced images does not provide a differential diagnosis [31]. However, the diagnostic specificity had improved in more recent MRI sequences. Thus, the increased cellularity of recurrent tumors generates low ADC values on diffusion-weighted imaging (DWI). However, numerous post-radiation effects could interfere with this diagnosis. A threshold of 2.6 for rCBV max seems to be a good indication of tumor recurrence, like a combination of the Cho.Cr and Cho/Naa thresholds in which the sensitivity and specificity of results were clearly improved by combining at least two parameters [33]. Finally, Amide Proton Transfer (APT) is a novel molecular imaging technique. Because of its hypercellularity, a

progressive glioma is hyperintense on APT sequences while radiation necrosis is hypointense [34]).

## Models to improve understanding

As mentioned above, there are intracranial MRI results from more than twenty studies, making global analysis of these data difficult. How can these parameters be integrated into a coherent whole? Two approaches have been suggested in the past few years.

The first approach is based on the simple observation of the millimetric spatial resolution of MR spectroscopic images to obtain a tumor volume growth curve. This is then included in a mathematical model to characterize individual tumor dynamics. The proliferation-diffusion equation takes into account both tumor growth and parenchymal infiltration via the diffusion of tumor cells resulting in a new parameter with a strong prognostic value.

The second approach analyzes the metabolic changes in low-grade gliomas that precede the morphological changes during the sometimes long progression of this disease, in particular using MR spectroscopy and perfusion. Tumor metabolism adjusts to growing hypoxia by modifying lactate transporters and increasing anaerobic glycolysis. This biomathematical model, which has been described in several articles, defines several LGG subtypes, including certain that represent an borderline between WHO grade II and III gliomas, and whose detection during follow-up can be

especially important for therapeutic management of these tumors [35].

### Conclusion

Conceptually, gliomas should now be considered a dynamic multiparametric entity. Indeed, the progression of MR spectroscopic features over time confirms the importance of monitoring tumor progression with this imaging technique. This has created new problems associated with reproducibility (intra- and inter center) of tests, which must be performed on the same machine in the same patients while avoiding comparison of results of certain sequences obtained from 1.5 and 3 Tesla machines. Sequences should also be read and treated on the same console with the same software. Finally, the results of these tests and patient files should be discussed in national multidisciplinary meetings.

#### TAKE-HOME MESSAGES

- Multiparametric MRI plays an essential role in the initial assessment of low-grade gliomas because it provides information on tumor aggressivity and potential progression in young adults even before biopsy.

- There are correlations between multiparametric MRI and immunohistochemistry results.
- There are correlations between multiparametric MRI and molecular biology results.
- Tumor volumetrics, perfusion imaging, and MR spectroscopy are complementary tests for the intermediate and short-term follow-up of LGG.
- These data can be included in predictive models of tumor progression for individual patients.

### Clinical case

A 31-year-old man was referred to the radiology unit for MRI to assess an initial epileptic crisis (Fig. 4). Results showed a tumor in the left temporoparietal junction with standard MRI, features suggesting low-grade glioma.

### Questions

- 1) What are the arguments to support this diagnosis?
- 2) Multiparametric imaging results identify certain pathological features; what are they?
- 3) What is the prognostic value of an increase in rCBV?
- 4) Is the presence of T1-weighted gadolinium enhancement a negative predictive factor?
- 5) What is the most reliable MRI marker of short and intermediate term tumor progression?

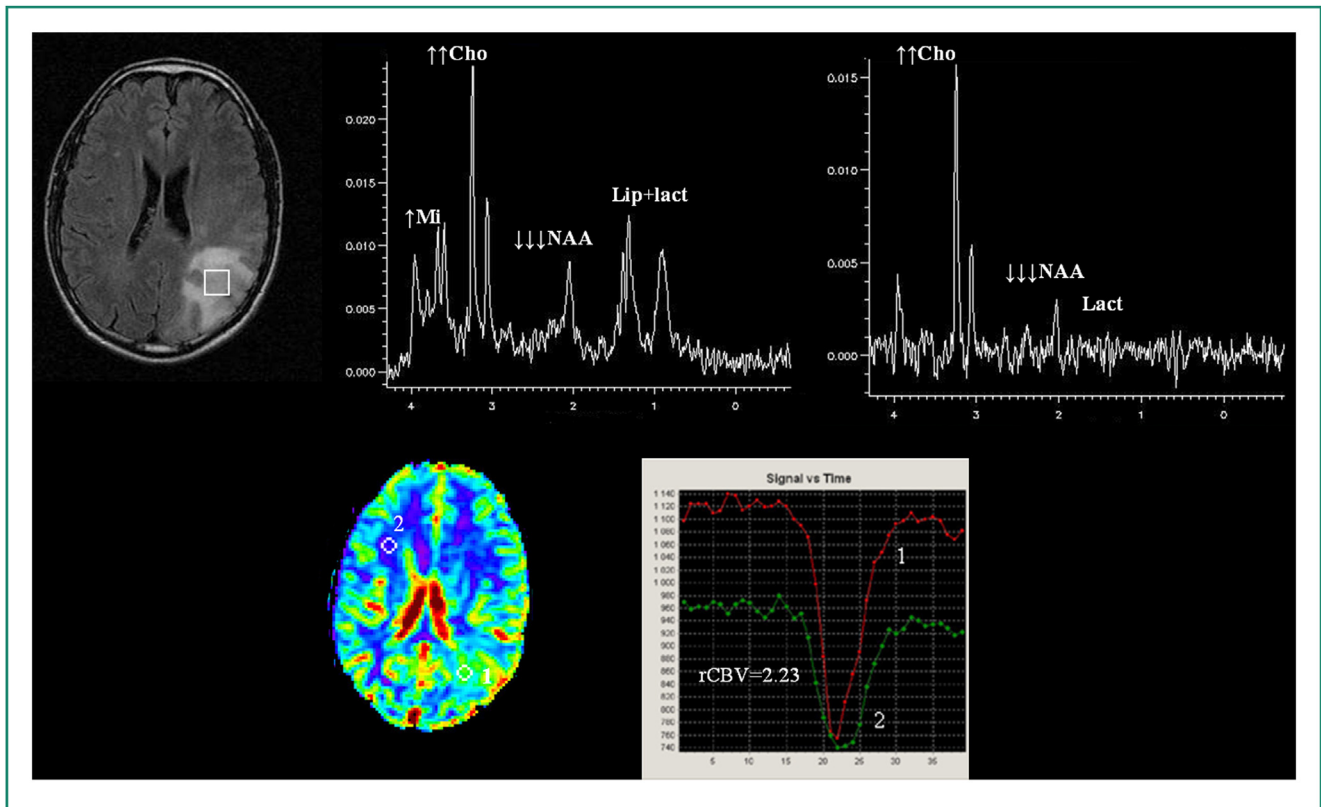


Figure 4. Multiparametric file of a glioma in the left temporoparietal junction. The CNI is above 5, with mobile lipids and lactate resonance. The rCBV is 2.23.

## Answers

- 1) A fairly homogenous tumor on all sequences, with undefined margins, little or no gadolinium enhancement and no necrotic cavitation or hemorrhagic changes.
- 2) Elevated CNI, mobile lipids and lactate resonance. Mobile lipid resonance is predictive of a Ki-67 above 8%, an elevated value for this grade tumor. Lactate resonance is predictive of an rCBV above 1.7, which is indeed the case.
- 3) Significantly reduced progression-free survival because this value is above 1.7, which is the case.
- 4) No, not alone because this is the case in 20 to 30% of LGG, regardless of the prognosis. Only the presence of T1-weighted gadolinium enhancement during follow-up can be considered a marker of tumor progression.
- 5) The average transverse diameter obtained from tumor volumetrics.

## Disclosure of interest

The authors declare that they have no conflicts of interest concerning this article.

## References

- [1] Bonavita S, Di Salle F, Tedeschi G. Proton MRS in neurological disorders. *Eur J Radiol* 1999;30(2):125–31.
- [2] Smith I, Stewart L. Magnetic resonance spectroscopy in medicine: clinical impact. *Prog Nucl Magn Reson Spectroscopy* 2002;40(1):1–34.
- [3] Dumas-Dupont C, Koziak M, Miquel C, Nataf F, Jouvet A, Varlet P. [Reappraisal of the Sainte-Anne Hospital classification of oligodendrogliomas in view of retrospective studies]. *Neurochirurgie* 2005;51:247–53.
- [4] Kreth FW, Faist M, Grau S, Ostertag CB. Interstitial 125I radio-surgery of supratentorial de novo WHO Grade 2 astrocytoma and oligoastrocytoma in adults: long-term results and prognostic factors. *Cancer* 2006;106(6):1372–81.
- [5] Pallud J, Capelle L, Taillandier L, Fontaine D, Mandonnet E, Guillevin R, et al. Prognostic significance of imaging contrast enhancement for WHO grade II gliomas. *Neurooncol* 2009;11(2):176–82.
- [6] Kato Y, Higano S, Tamura H, Mugikura S, Umetsu A, Murata T, et al. Usefulness of contrast-enhanced T1-weighted sampling perfection with application-optimized contrasts by using different flip angle evolutions in detection of small brain metastasis at 3T MR imaging: comparison with magnetization-prepared rapid acquisition of gradient echo imaging. *AJNR Am J Neuroradiol* 2009;30(5):923–9.
- [7] Nagao E, Yoshiura T, Hiwatashi A, Obara M, Yamashita K, Kamano H, et al. 3D turbo spin-echo sequence with motion-sensitized driven-equilibrium preparation for detection of brain metastases on 3T MR imaging. *AJNR Am J Neuroradiol* 2011;32(4):664–70.
- [8] Bian W, Khayal IS, Lupo JM, McGue C, Vandenberg S, Lamborn KR, et al. Multiparametric characterization of grade 2 glioma subtypes using magnetic resonance spectroscopic, perfusion, and diffusion imaging. *Transl Oncol* 2009;2(4):271–80.
- [9] Brown RA, Frayne R. A comparison of texture quantification techniques based on the Fourier and S transforms. *Med Phys* 2008;35(11):4998–5008.
- [10] Guillevin R, Manuel C, Duffau H, Kujas M, Capelle L, Aubert A, et al. Proton magnetic resonance spectroscopy predicts proliferative activity in diffuse low-grade gliomas. *J Neurooncol* 2008;87(2):181–7.
- [11] Mescher M, Merkle H, Kirsch J, Garwood M, Gruetter R. Simultaneous in vivo spectral editing and water suppression. *NMR Biomed* 1998;11(6):266–72.
- [12] Guillevin R, Manuel C, Vallee JN, Françoise JP, Capelle L, Habas C, et al. Mathematical modeling of energy metabolism and hemodynamics of WHO grade II gliomas using in vivo MR data. *C R Biol* 2011;334(1):31–8.
- [13] Griguer CE, Oliva CR, Gillespie GY. Glucose metabolism heterogeneity in human and mouse malignant glioma cell lines. *J Neurooncol* 2005;74(2):123–33.
- [14] Danchaivijitr N, Waldman AD, Tozer DJ, Benton CE, Brasil Caseiras G, Tofts PS, et al. Low-grade gliomas: do changes in rCBV measurements at longitudinal perfusion-weighted MR imaging predict malignant transformation? *Radiology* 2008;247(1):170–8.
- [15] Caseiras GB, Chheang S, Babb J, Rees JH, Peccerelli N, Tozer DJ, et al. Relative cerebral blood volume measurements of low-grade gliomas predict patient outcome in a multi-institution setting. *Eur J Radiol* 2010;73(2):215–20.
- [16] Law M, Young RJ, Babb JS, Peccerelli N, Chheang S, Gruber ML, et al. Gliomas: predicting time to progression or survival with cerebral blood volume measurements at dynamic susceptibility-weighted contrast-enhanced perfusion MR imaging. *Radiology* 2008;247(2):490–8.
- [17] Callot V, Galanaud D, Figarella-Branger D, Lefur Y, Metellus P, Nicoli F, et al. Correlations between MR and endothelial hyperplasia in low-grade gliomas. *J Magn Reson Imaging* 2007;26(1):52–60.
- [18] Xu M, See SJ, Ng WH, Arul E, Back MF, Yeo TT, et al. Comparison of magnetic resonance spectroscopy and perfusion-weighted imaging in presurgical grading of oligodendroglial tumors. *Neurosurgery* 2005;56(5):919–26.
- [19] Yang D, Korogi Y, Sugahara T, Kitajima M, Shigematsu Y, Liang L, et al. Cerebral gliomas: prospective comparison of multivoxel 2D chemical-shift imaging proton MR spectroscopy, echoplanar perfusion and diffusion-weighted MRI. *Neuroradiology* 2002;44(8):656–66.
- [20] Mauz N, Krainik A, Tropres I, Lamalle L, Sellier E, Eker O, et al. Perfusion magnetic resonance imaging: comparison of semiologic characteristics in first-pass perfusion of brain tumors at 1.5 and 3 Tesla. *J Neuroradiol* 2012;39(5):308–16.
- [21] Dhermain F, Saliou G, Parker F, Page P, Hoang-Xuan K, Lacroix C, et al. Microvascular leakage and contrast enhancement as prognostic factors for recurrence in unfavorable low-grade gliomas. *J Neurooncol* 2010;97(1):81–8.
- [22] Aronen HJ, Pardo FS, Kennedy DN, Belliveau JW, Packard SD, Hsu DW, et al. High microvascular blood volume is associated with high glucose uptake and tumor angiogenesis in human gliomas. *Clin Cancer Res* 2000;6(6):2189–200.
- [23] Ricard D, Kaloshi G, Amiel-Benouaich A, Lejeune J, Marie Y, Mandonnet E, et al. Dynamic history of low-grade gliomas before and after temozolomide treatment. *Ann Neurol* 2007;61(5):484–90.
- [24] Hoang-Xuan K, Capelle L, Kujas M, Taillibert S, Duffau H, Lejeune J, et al. Temozolomide as initial treatment for adults with low-grade oligodendrogliomas or oligoastrocytomas and correlation with chromosome 1p deletions. *J Clin Oncol* 2004;22(15):3133–8.
- [25] Gill SS, Thomas DG, Van Bruggen N, Gadian DG, Peden CJ, Bell JD, et al. spectroscopy of intracranial tumours: in vivo and in vitro studies. *J Comput Assist Tomogr* 1990;14(4):497–504.
- [26] Murphy PS, Viviers L, Abson C, Rowland IJ, Brada M, Leach MO, et al. Monitoring temozolomide treatment of low-grade glioma with proton magnetic resonance spectroscopy. *Br J Cancer* 2004;90(4):781–6.

- [27] Guillevin R, Menuel C, Taillibert S, Capelle L, Costalat R, Abud L, et al. Predicting the outcome of grade II glioma treated with temozolomide using proton magnetic resonance spectroscopy. *Br J Cancer* 2011;104:1854–61.
- [28] Miller BL, Chang L, Booth R, Ernst T, Cornford M, Nikas D, et al. In vivo <sup>1</sup>H MRS choline: correlation with in vitro chemistry/histology. *Life Sci* 1996;58(22):1929–35.
- [29] Byrne TN. Response of low-grade oligodendroglial tumors to temozolomide. *J Neurooncol* 2004;70(3): 279–80.
- [30] Chinot O. Chemotherapy for the treatment of oligodendroglial tumors. *Semin Oncol* 2001;28(4 Suppl. 13):13–8.
- [31] Kumar AJ, Leeds NE, Fuller GN, Van Tassel P, Maor MH, Sawaya RE, et al. Malignant gliomas: MR imaging spectrum of radiation therapy- and chemotherapy-induced necrosis of the brain after treatment. *Radiology* 2000;217(2):377–84.
- [33] Matsusue E, Fink JR, Rockhill JK, Ogawa T, Maravilla KR. Distinction between glioma progression and post-radiation change by combined physiologic MR imaging. *Neuroradiology* 2010;52(4):297–306.
- [34] Zhou J, Tryggstad E, wen Z, Lal B, Zhou T, Grossmann R, et al. Differentiation between glioma and radiation necrosis using molecular magnetic resonance imaging of endogenous proteins and peptides. *Nature Med* 2010.
- [35] Costalat R, Francoise JP, Menuel C, Lahutte M, Vallée JN, De Marco G, et al. Mathematical modeling of metabolism and hemodynamics of lactate for analysis of low grade gliomas. *Acta Biotheor* 2012;60:99–107.